

Ventricular fibrillation development following atrial fibrillation after the ingestion of sildenafil in a patient with Wolff-Parkinson-White syndrome

Sinan Inci^{1,*}, Ibrahim Izgu¹, Halil Aktas¹, Pinar Dogan¹, Ali Dogan²

¹ Department of Cardiology, Aksaray State Hospital, Aksaray, Turkey;

² Department of Cardiology, Medical Faculty, Erciyes University, Kayseri, Turkey.

Summary Complications in the accessory pathway in Wolff-Parkinson-White (WPW) syndrome could cause different clinical conditions by inducing different arrhythmias. Atrial fibrillation (AF) is one of these arrhythmias and is important as it causes life-threatening arrhythmias. It is known that some drugs, underlying cardiac diseases, and the number of accessory pathways, cause a predisposition to this condition. In the current report, we presented a patient with WPW who was admitted to the emergency department with AF, wide QRS and a rapid ventricular response that progressed to ventricular fibrillation.

Keywords: Atrial fibrillation, sildenafil, Wolff-Parkinson-White syndrome

1. Introduction

Sildenafil is an oral agent used in the treatment of erectile dysfunction (ED). It demonstrates its action by the potent inhibition of phosphodiesterase type 5 enzyme (PDE5) in cavernous tissue, thus increasing nitric oxide (NO) and cyclic 3', 5'-guanosine monophosphate (cGMP) levels and prolonging smooth muscle relaxation (1). In contrast to initial prejudices, this drug continues to be used in individuals with cardiovascular disease. Moreover, in a few case reports this drug has been demonstrated to induce arrhythmias in the presence of underlying cardiac pathological conditions (2-4). We reported a patient with Wolff-Parkinson-White (WPW) syndrome in which atrial fibrillation developed a short period after the ingestion of sildenafil citrate, and subsequently progressed to ventricular fibrillation.

2. Case Report

A thirty-seven year old male patient, without any atherosclerotic risk factors, was admitted to the

emergency department complaining of palpitations and shortness of breath that had begun about an hour ago previously. In his anamnesis, he reported that his symptoms started 20 minutes after taking sildenafil, prior to any sexual contact, and progressively increased. He had undergone an examination seven years previously, following complaints of palpitation, and was diagnosed with WPW syndrome. Although he had occasionally had palpitations, previously they had never been so severe. He said that he had used medication for one year after the initial diagnosis but he had then stopped using the drug. Following a physical examination his BP: 85/54 mm Hg, pulse: 180/min and other systemic examinations appeared normal. Electrocardiography (ECG) detected atrial fibrillation with wide QRS, and rapid ventricular response (Figure 1). There was no abnormality in laboratory results. Initially, his medical treatment was planned using Cordarone. As sinus rhythm could not be achieved, D&C with 200 joule was planned. Ventricular fibrillation developed while the patient was being sedated. Therefore defibrillation was performed and sinus rhythm was achieved. The patient's Basal ECG was consistent with Wolf-Parkinson-White syndrome (Figure 2). In transthoracic echocardiography, all wall motions and valve structures were found to be normal. The ejection fraction (EF) was 58%. There were not any findings to suspect myocardial ischemia. The patient was followed up in the coronary intensive care

*Address correspondence to:

Dr. Sinan Inci, Aksaray State Hospital, Zafer Mahallesi Nevşehir caddesi No:117, Aksaray, Turkey.
E-mail: doktorsinaninci@gmail.com

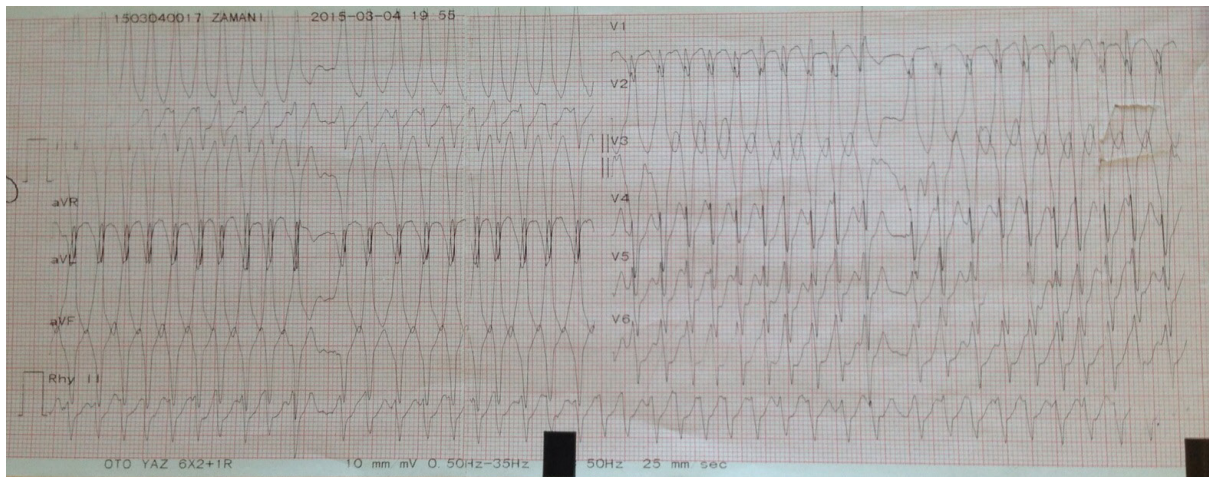


Figure 1. Atrial fibrillation with wide QRS and high ventricular response in the emergency department.

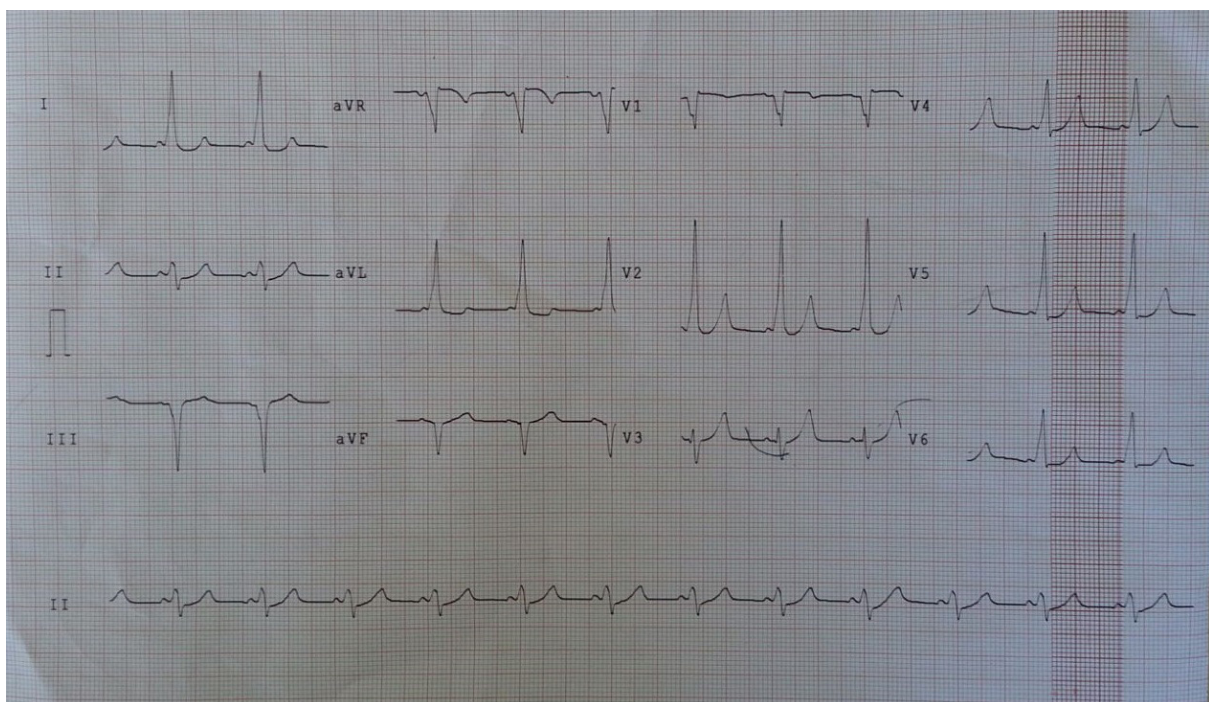


Figure 2. Twelve lead ECG showing characteristic delta waves and short PR interval of WPW Syndrome.

unit for three days and no complications developed. Electrophysiological study was performed and the accessory pathways were treated with catheter ablation. The patient was discharged without any complications. There were no cardiac complications on a third and six month follow-up.

3. Discussion

Incidences of AF in WPW syndrome is reported to be between 11% and 30%, higher than the normal population. In previous studies, it has been reported that sudden cardiac death occurs in patients with WPW each year, approximately at a rate of 0.15% and it has been demonstrated that the reason for these deaths are ventricular fibrillation caused by atrial fibrillation with

rapid ventricular response (5).

Since its approval by the Food and Drug Administration (FDA) in 1998, sildenafil has been used by millions of individuals worldwide (6) and has been well tolerated in the general population. Most of the side effects are minor, transient and dose dependent. In particular cases, when taken with organic nitrates, it can lead to severe hypotension. It is contraindicated in cases with acute coronary syndrome, life threatening arrhythmias and a recent history of stroke. The FDA has reported that it is necessary to use the drug carefully during the first six months following a recent myocardial infarction, in patients with hypotension, congestive heart disease (CHD) and severe hypertension (7).

Some predisposing factors for the development of AF in patients with WPW syndrome have been defined.

The presence of more than one accessory pathway, R-R interval shorter than 260 msec and drugs used in reciprocal tachycardias, such as verapamil, are the foremost among these (1,8,9). Hayashi *et al.* (2) have reported a similar case to this study, where the patient developed AF with rapid ventricular response and hypotension after using sildenafil. As he had had no response to cardioversion, it is probable that the rhythm spontaneously returned to normal following the drug's action time. But unlike the current case, a fatal arrhythmia such as VF didn't develop. In the case presented by Awan *et al.* (4), AF with rapid ventricular response developed in a patient with HCMP on two occasions within a six-week period following the ingestion of sildenafil but sinus rhythm returned with medical treatment. In the current case, AF with rapid ventricular response and subsequently fatal arrhythmia, VF, developed a short period after sildenafil use. It is not clear with these patients what mechanism from sildenafil produces a predisposition to AF. The most probable explanation is that sildenafil causes arterial vasodilatation, and as a result of developing hypotension causes increased activation in the sympathetic system. Increased sympathetic system activation might be one of the reasons that induces AF, as the effective refractory period of the accessory pathways is short, and the ventricular response in atrial fibrillation might have been quite rapid, causing ventricular fibrillation to develop.

In conclusion, the use of sildenafil and similar drugs in patients with WPW, might cause atrial fibrillation and subsequently fatal cardiac arrhythmias. We believe that patients with an underlying cardiac pathology in particular, should be pre-warned and care should be taken before such drugs are recommended.

References

1. Ghofrani HA, Osterloh IH, Grimminger F. Sildenafil: From angina to erectile dysfunction to pulmonary hypertension and beyond. *Nat Rev Drug Discov.* 2006; 5:689-702.
2. Hayashi K, Minezaki KK, Narukawa M, Ookubo M, Mitsuhashi T, Shimada K. Atrial fibrillation and continuous hypotension induced by sildenafil in an intermittent WPW syndrome patient. *Jpn Heart J.* 1999; 40:827-830.
3. Shah PK. Sildenafil in the treatment of erectile dysfunction. *N Engl J Med.* 1998; 339:699.
4. Awan GM, Calderon E, Dawood G, Alpert MA. Acute, symptomatic atrial fibrillation after sildenafil citrate therapy in a patient with hypertrophic obstructive cardiomyopathy. *Am J Med Sci.* 2000; 320:69-71.
5. Centurión OA, Shimizu A, Isomoto S, Konoe A. Mechanisms for the genesis of paroxysmal atrial fibrillation in the Wolff Parkinson-White syndrome: Intrinsic atrial muscle vulnerability vs. electrophysiological properties of the accessory pathway. *Europace.* 2008; 10:294-302.
6. Sadovsky R, Miller T, Moskowitz M, Hackett G. Three-year update of sildenafil citrate (Viagra) efficacy and safety. *Int J Clin Pract.* 2001; 55:115-128.
7. Kloner RA, Jaron JP. Erectile dysfunction and sildenafil citrate and cardiologists. *Am J Cardiol.* 1999; 83:576-582.
8. Wellens HJJ, Bar FW, Fare J, Ross D, Vanagt EJ. Sudden death in the Wolff-Parkinson-White syndrome. In: Sudden Death, HE Kulbertus, HJJ Wellens (eds.). Sudden death, 1980. Martinus Nijhoff, Boston, 1980, pp.392-399.
9. Wyndham CR, Amat-y-Leon F, Wu D, Denes P, Dhingra R, Simpson R, Rosen KM. Effects of cycle length on atrial vulnerability. *Circulation.* 1977; 55:260-267.

(Received July 29, 2015; Revised August 6, 2015; Accepted August 12, 2015)