

Current research on pediatric patients with bronchiolitis obliterans in Brazil

Silvia Onoda Tomikawa*, Joaquim Carlos Rodrigues

Pediatric Pulmonology Division, Children's Institute, Clinical Hospital, University of São Paulo, Brazil.

Summary

Bronchiolitis obliterans (BO) is a rare but severe disease, characterized by inflammation and fibrosis of the terminal bronchioles. BO in children usually occurs after a severe lung viral infection. Diagnosis is based on clinical history of acute bronchiolitis followed by persistent obstruction of the airways and characteristic findings in HRCT. There is no consensus on treatment beyond supportive measures, but bronchodilators and corticosteroids are often used. This review describes the clinical and radiological characteristics and outcomes of BO in pediatric patients, with an emphasis on current research in Brazil.

Keywords: Bronchiolitis obliterans, children, obstructive pulmonary disease

1. Introduction

Bronchiolitis obliterans (BO) is a rare chronic obstructive lung disease that occurs following a severe injury to the lower respiratory tract and results in partial or complete obliteration of the small airways (1,2). BO has several etiologies, but in children the disease usually occurs post-infection (1,2). Several viruses have been associated with BO (2,3), such as respiratory syncytial virus, parainfluenza, influenza, and adenovirus; the latter in particular is associated with the most severe form of the disease.

Post-infectious BO is prevalent especially in some regions in Asia and the southern cone of South America (the south of Brazil, Uruguay, Argentina, and Chile) (4,5). The reasons for this high prevalence of post-infectious BO in these regions are not clear and may be due to more aggressive infectious agents, load or infection due to crowding, some constitutional/genetic predisposition, or even environmental factors (5). Therefore, there are several centers in Brazil like the

current author's that study BO in children.

Although the prevalence of BO in Brazil is not known, it is presumably quite low. In the city of Curitiba, 48 pediatric patients were studied over 11 years of outpatient treatment (6). In the city of Porto Alegre, Zhang *et al.* (7) studied 31 pediatric patients over 18 years of monitoring and Bosa *et al.* (8) was studied the nutritional status of 57 pediatric patients followed up at two referral hospitals. In the city of Fortaleza (9), 35 pediatric patients were studied over five years. Finally, a study by the current authors at the Clinical Hospital affiliated with the Faculty of Medicine of the University of São Paulo (10) included 40 patients over 11 years of outpatient treatment.

The reason why some children develop BO is not fully understood. Factors such as viral genotype, host immune response, genetic predisposition, and environmental influences may be associated with disease severity in acute and long-term sequelae (11). Previous studies (2,12-14) found that risk factors for developing BO in children are adenoviral infection and the severity of acute illness (duration of hospitalization, admission to an intensive care unit, mechanical ventilation, oxygen use, corticosteroid treatment, and β 2 agonist administration).

2. Histopathology

BO is characterized by inflammation and fibrosis of the terminal bronchioles with narrowing or complete obliteration of the lumens of the small airways, as

Released online in J-STAGE as advance publication December 25, 2014.

*Address correspondence to:

Dr. Silvia Onoda Tomikawa, Pediatric Pulmonology Division, Children's Institute, Clinical Hospital, University of São Paulo, Rua Bianchi Bertoldi, 166 apt101, CEP 05422-070 São Paulo, SP, Brazil.

E-mail: silviatomi@yahoo.com.br

shown in Figure 1 (15). Mauad *et al.* of the Faculty of Medicine of the University of Sao Paulo examined 34 biopsy specimens from open lung lobectomy, lobe excision, and autopsies, and they described histological aspects of BO (16). Their study found that 97% of childhood BO was constrictive, with variable degrees of inflammation and airway obliteration.

3. Clinical and radiological aspects

The initial symptoms and signs of BO are similar to acute viral bronchiolitis: fever, cough, tachypnea, and

Table 1. Symptoms and signs at time of diagnosis of 40 children with BO

Characteristics (n = 40)	n (%)
Symptoms	
Persistent cough	23 (57.5)
Dyspnea	26 (65)
Persistent wheezing	40 (100)
Cyanosis (reported episodes)	9 (22.5)
Physical examination	
Increased antero-posterior diameter of the chest	23 (57.5)
Aspects similar to Cushing syndrome	8 (20)
Clubbing of the fingers	7 (17.5)
Watch-glass nails	2 (5)
Pulmonary auscultation	
Diffuse crackles	24 (60)
Localized crackles	7 (17.5)
Wheezing	33 (82.5)

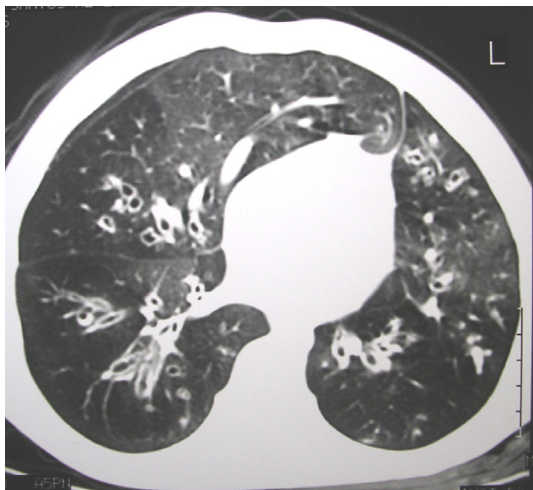


Figure 1. HRCT of a pediatric patient with post-infectious BO.

Table 2. HRCT findings in children with BO

HRCT findings (n = 40)	n (%)
Mosaic pattern of perfusion	29 (72.5)
Bronchial wall thickening	18 (45)
Atelectasis	16 (40)
Alveolar filling	12 (30)
Bronchiectasis	11 (27.5)
Hyperinflation	5 (12.5)
Air trapping	5 (12.5)
Swyer-James-MacLeod syndrome	1 (2.5)

wheezing (1,3). But the disease does not progress as expected and symptoms and signs persist for weeks or months. Patients with BO have tachypnea, dyspnea, hypoxemia, crackles, wheezing, an increased antero-posterior diameter of the chest, digital clubbing, and cyanosis (3,7,12,17). In a previous study by the current authors (10), the most common symptoms and signs of BO in 40 patients were wheezing, dyspnea, and coughing (Table 1).

Imaging techniques play an important role in the diagnosis for post-infectious BO (15). The three most common methods of imaging are conventional chest radiographs (CRX), lung ventilation/perfusion scans (V/Q scan), and high-resolution chest tomography (HRCT) (15). HRCT is more sensitive than CRX and V/Q scan at detecting airway and parenchymal abnormalities (15). Brazilian studies (6,9,10,18) found that characteristic findings in HRCT were: a mosaic pattern of perfusion, bronchiectasis, bronchial wall thickening, air trapping, and atelectasis. These findings are shown in Figure 1. A previous study by the current authors (10) revealed the most frequent findings for HRCT, as shown in Table 2.

4. Pulmonary function testing

Pulmonary function is severely compromised in children with post-infectious BO (19). Patients typically exhibit severe fixed air-flow obstructions with little or no response to bronchodilator, increased airway resistance, decreased compliance, a reduced expiratory flow, air trapping, and increased residual volume (1,7,11,17,19).

Mattiello *et al.* studied the lung function of children with BO (20). Seventeen patients had a reduced FVC, FEV₁, and FEF_{25-75%}, an increased total lung capacity (TLC) and residual volume (RV), and a reduced functional exercise capacity undergoing a cardiopulmonary exercise test (CPET) and a 6-minute walk test (6MWT) (Table 3).

5. Diagnosis

Studies have proposed the following criteria for the diagnosis of post-infectious BO (5,11) : i) A history

Table 3. Spirometric and plethysmographic parameters of 20 patients with BO (adapted from Mattiello)

Parameter	Mean value + S.D.	% predicted + S.D.
FVC (L)	1.7 + 0.6	66.8 + 17.3
FEV ₁ (L)	0.9 + 0.4	57.7 + 17.9
FEV ₁ /FVC (%)	57.9 + 12.5	
FEF _{25-75%} (L)	0.5 + 0.2	20.4 + 12.6
TLC (L)	4.1 + 1.1	121.2 + 23.2
RV (L)	2.4 + 0.7	294.3 + 83.3
RV/TLC (%)	59.1 + 8.4	

*PFT = pulmonary function test, TLC = total lung capacity, RV = residual volume

of acute bronchiolitis in a previously healthy infant; *ii*) Airway obstruction detected either by physical examination and/or by lung function tests that persists for over 6 weeks after the initial event despite the use of bronchodilators and steroids; *iii*) HRTC exhibiting bronchiectasis and/or a mosaic pattern; *iv*) Exclusion of other chronic obstructive pulmonary diseases, such as cystic fibrosis, severe asthma, bronchopulmonary dysplasia, foreign body aspiration, aspiration pneumonia associated with gastroesophageal reflux, tracheomalacia, congenital malformation, tuberculosis, AIDS, and other immunodeficiency diseases.

Thus, an open lung biopsy should be considered only when histological confirmation is needed. Furthermore, a biopsy cannot always confirm a diagnosis due to the heterogeneous distribution of pulmonary lesions; the specimens obtained may exhibit only mild histological changes that may go unnoticed (1,5,11).

Table 4. Differences in all time point assessment vs. baseline in the tiotropium vs. placebo group in the main PFT measurements (reprinted from Teixeira)

PFT parameter	Friedman Test	P value
FVC	18.171	0.33
FEV1	48.184	< 0.0001
RV	45.037	< 0.0001
Resistance	101.10	< 0.0001
Conductance	136.83	< 0.0001

6. Treatment

There is no consensus on bronchiolitis obliterans treatment. Supportive measures are important and include not smoking, vaccination against influenza, respiratory physiotherapy, supplemental oxygen at home for hypoxemic patients, and nutritional assistance (1,3,5,11,21). Bosa *et al.* (8) assessed the nutritional status of 57 children with BO and found a high rate of malnutrition (21.7%) and risk of malnutrition (17.5%), indicating the need for nutritional intervention in those patients.

Bronchodilators are used to treat symptomatic wheezing, although BO has been considered a fixed obstructive disease of the small airways that does not respond or that responds poorly to bronchodilators (19). In a Brazilian study by Teixeira *et al.*, administration of a single dose of tiotropium to 30 patients with post-infectious BO resulted in a continued decrease in bronchial obstruction and air trapping for up to 24 hours (19) (Table 4).

The use of corticosteroids in the treatment of BO is based on the study by Moran and Hellstrom (22), who used a rabbit model of BO to demonstrate the natural course of the disease and that corticosteroid therapy in the early phase of illness modified fibroblastic response. However, similar studies were not performed in humans, so use of corticosteroids to treat BO remains controversial (1,7,11).

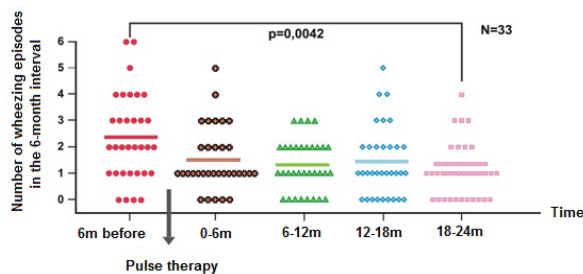


Figure 2. Exacerbation of wheezing before and after pulse therapy (n = 33).

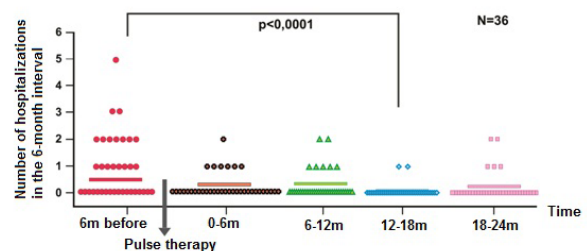


Figure 3. Hospitalization before and after pulse therapy (n = 36).

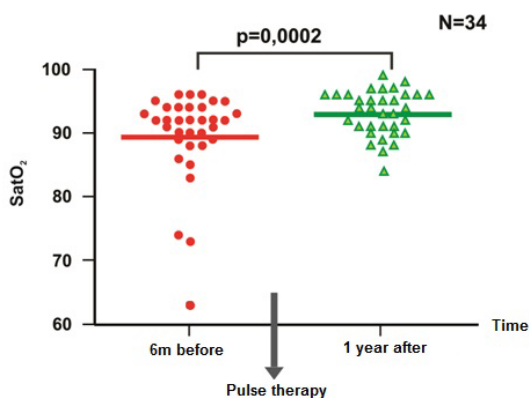


Figure 4. Oxygen saturation (SatO2) before and after 1 year of pulse therapy (n = 34).

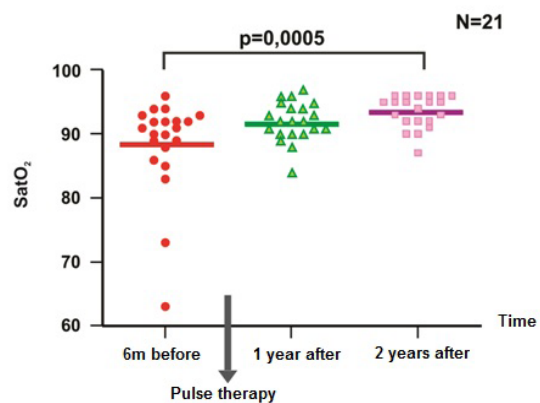


Figure 5. Oxygen saturation (SatO2) before and after 1 and 2 years of pulse therapy (n = 21).

Zhang *et al.* (7) advocated systemic use of corticosteroids, arguing that severe respiratory obstruction would prevent an aerosol spray from reaching the peripheral airways. Other clinicians prefer to use inhaled corticosteroids to minimize systemic adverse effects and to reduce bronchial hyperreactivity (21).

Methylprednisolone intravenous pulse therapy has been proposed to reduce adverse reactions to prolonged systemic administration of oral corticosteroids and is an alternative for patients with more severe disease (1,11,17). In a previous study by the current authors (10), 40 children with BO were treated with high-dose methylprednisolone pulse therapy, and these children exhibited clinical improvement as indicated by decreased exacerbation of wheezing and improved oxygen saturation. As a result, these patients had fewer instances of hospitalization (Figures 2-5).

7. Outcome and prognosis

During an acute adenoviral infection, mortality can be as high as 18.4% (13,14), but once an infection has been established BO has a low mortality rate (15). Patients with post-infectious BO, in contrast to those with post-transplant BO, usually exhibit clinical improvement after 2-3 years of supportive treatment, although clinical and radiological changes and changes in pulmonary function may persist (7,9,12,23).

As the lungs develop, the diameter of the airways increases and the airways become less susceptible to obstruction. Thus, the clinical improvement observed may occur as a result of normal lung development and not represent a regression of lesions (7). In a study by Zhang *et al.* (7), 22.6% of patients had clinical remission, 67.7% of patients continued to have symptoms, and 9.7% of patients died.

However, a study by Cazzato *et al.* (24) yielded worrying findings indicating increased lung dysfunction (a decline in FEV₁ of 1.01% and a decline in FEF_{25-75%} of 1.04% per year) over time in patients with post-infectious BO, suggesting that BO may be a progressive lung disorder. Additional studies need to be performed to understand the process of inflammation caused by the disease and the better approaches to its treatment.

References

1. Moonnumakal SP, Fan LL. Bronchiolitis obliterans in children. *Curr Opin Pediatr.* 2008; 20:272-278.
2. Colom AJ, Teper AM, Vollmer WM, Diette GB. Risk factors for the development of bronchiolitis obliterans in children with bronchiolitis. *Thorax.* 2006; 61:503-506.
3. Zhang L, Silva FA. Bronchiolitis obliterans in children. *J Pediatr (Rio J).* 2000; 76:185-192. (in Portuguese)
4. Kajon AE, Mistchenko AS, Videla C, Hostal M, Wadell G, Avandaño LF. Molecular epidemiology of adenovirus acute lower respiratory infections of children in the south cone of South America (1991-1994). *J Med Virol.* 1996; 48:151-156.
5. Jones MH, Pitrez PM, Stein RT. Post-infectious bronchiolitis obliterans. *Pediatr Pulmonol Suppl.* 2004; 26:64-65.
6. dos Santos RV, Rosario NA, Ried CA. Post-infectious bronchiolitis obliterans: Clinical aspects and complementary testing of 48 children. *J Bras Pneumol.* 2004; 30:20-25.
7. Zhang L, Irion K, Kozakewich H, Camargo JJ, da Silva Porto N, Abreu e Silva FA. Clinical course of postinfectious bronchiolitis obliterans. *Pediatr Pulmonol.* 2000; 29:341-350.
8. Bosa VL, Mello ED, Mocelin HT, Benedetti FJ, Fischer GB. Assessment of nutritional status in children and adolescents with post-infectious bronchiolitis obliterans. *J Pediatr (Rio J).* 2008; 84:323-330.
9. Lino CA, Batista AKM, Soares MAD, de Freitas AEH, Gomes LC, Filho JHM, Gomes VC. Bronchiolitis obliterans: Clinical and radiological profile of children followed-up in a reference out-patient clinic. *Rev Paul Pediatr.* 2013; 31:10-16. (in English and Portuguese)
10. Tomikawa SO, Adde FV, da Silva Filho LV, Leone C, Rodrigues JC. Follow-up on pediatric patients with bronchiolitis obliterans treated with corticosteroid pulse therapy. *Orphanet J Rare Dis.* 2014; 9:128.
11. Teper A, Fischer GB, Jones MH. Respiratory sequelae of viral diseases: From diagnosis to treatment. *J Pediatr (Rio J).* 2002; 78:S187-S194. (in Portuguese)
12. Chiu CY, Wong KS, Huang YC, Lin TY. Bronchiolitis obliterans in children: Clinical presentation, therapy and long-term follow-up. *J Paediatr Child Health.* 2008; 44:129-133.
13. Castro-Rodriguez JA, Daszenies C, Garcia M, Meyer R, Gonzales R. Adenovirus pneumonia in infants and factors for developing bronchiolitis obliterans: A 5-year follow-up. *Pediatr Pulmonol.* 2006; 41:947-953.
14. Murtagh P, Giubergia V, Viale D, Bauer G, Pena HG. Lower respiratory infections by adenovirus in children. Clinical features and risk factors for bronchiolitis obliterans and mortality. *Pediatr Pulmonol.* 2009; 44:450-456.
15. Fischer GB, Sarria EE, Mattiello R, Mocelin HT, Castro-Rodriguez JA. Post infectious bronchiolitis obliterans in children. *Paediatr Respir Rev.* 2010; 11:233-239.
16. Mauad T, Dolhnikoff M, São Paulo Bronchiolitis Obliterans Study Group. Histology of childhood bronchiolitis obliterans. *Pediatr Pulmonol.* 2002; 33:466-474.
17. Kim CK, Kim SW, Kim JS, Koh YY, Cohen AH, Deterding RR, White CW. Bronchiolitis obliterans in the 1990s in Korea and the United States. *Chest.* 2001; 120:1101-1106.
18. Zhang L, Irion K, da Silva PN, Abreu e Silva F. High-resolution computed tomography in pediatric patients with postinfectious bronchiolitis obliterans. *J Thorac Imaging.* 1999; 14:85-89.
19. Teixeira MF, Rodrigues JC, Leone C, Adde FV. Acute bronchodilator responsiveness to tiotropium in postinfectious bronchiolitis obliterans in children. *Chest.* 2013; 144:974-980.
20. Mattiello R, Sarria EE, Stein R, Fischer GB, Mocelin HT, Barreto SS, Lima JA, Brandenburg D. Functional capacity assessment during exercise in children and adolescents with post-infectious bronchiolitis obliterans. *J Pediatr (Rio J).* 2008; 84:337-343.

21. Lobo AL, Guardiano M, Nunes T, Azevedo I, Vaz LG. Post-infectious bronchiolitis obliterans in children. *Rev Port Pneumol.* 2007; 13:495-509. (in English and Portuguese)
22. Moran TJ, Hellstrom HR. Bronchiolitis obliterans: An experimental study of the pathogenesis and the use of cortisone in modification of the lesions. *AMA Arch Pathol.* 1958; 66:691-707.
23. Chan A, Allen R. Bronchiolitis obliterans: An update. *Curr Opin Pulm Med.* 2004; 10:133-141.
24. Cazzato S, Poletti V, Bernardi F, Laroni L, Bertelli L, Colonna S, Zappulla F, Timoncini G, Cicognani A. Airway inflammation and lung function decline in childhood post-infectious bronchiolitis obliterans. *Pediatr Pulmonol.* 2008; 43:381-390.

(Received November 11, 2014; Revised December 3, 2014; Accepted December 4, 2014)