

Current research, diagnosis, and treatment of fragile X-associated tremor/ataxia syndrome

Zukhrofi Muzar, Reymundo Lozano*

UC Davis MIND Institute and Department of Pediatrics, UC Davis Medical Center, Sacramento, CA, USA.

Summary

Fragile X-associated tremor/ataxia syndrome (FXTAS) is caused by a premutation CGG-repeat expansion in the 5'UTR of the fragile X mental retardation 1 (*FMRI*) gene. The classical clinical manifestations include tremor, cerebellar ataxia, cognitive decline and psychiatric disorders. Other less frequent features are peripheral neuropathy and autonomic dysfunction. Cognitive decline, a form of frontal subcortical dementia, memory loss and executive function deficits are also characteristics of this disorder. In this review, we present an expansion of recommendations for genetic testing for adults with suspected premutation disorders and provide an update of the clinical, radiological and molecular research of FXTAS, as well as the current research in the treatment for this intractable complex neurodegenerative genetic disorder.

Keywords: FXTAS, tremor/ataxia, premutation carrier, *FMRI*, *FMRI* mRNA, FMPR, late-onset neurological disorder and neurodegenerative disorder

1. Introduction

The fragile X mental retardation 1 gene (*FMRI*) which causes fragile X syndrome if fully mutated (more than 200 CGG-repeats in the polymorphic region- 5'UTR), was discovered in 1991. This discovery led to the description of premutation carriers (individuals with smaller alleles, 55-200 CGG repeats) and was followed by a better understanding of the transition propensity, the expansion of the unstable allele of women with the premutation, and a better genetic counseling for risk of offspring with fragile X syndrome (the most common monogenetic form of autism and intellectual disability). Later on an intermediate allele was described (45-54 repeats) which has a variable risk for disorders that are associated with the premutation. Although before the discovery of the *FMRI* gene, Cronister and colleagues (1) had reported a much higher incidence of early ovarian failure (before the age of 40 years) in females premutation carriers (PMC), PMC were generally seen as clinically unaffected (2-4). After the description of fragile X-associated

primary ovarian insufficiency (FXPOI) in 1991 and FXTAS in 2001, there has been a general recognition that premutation alleles are associated with a wide range of clinical involvement. It is now widely recognized that PMC are at risk to develop a range of mild cognitive and behaviors problems during childhood and neurological, psychiatric and other immune-mediated disorders during adulthood (5). The prevalence of the *FMRI* premutation has been described to be 1 in 113 to 259 females and 1 in 260 to 813 males in the general population (6-11). This suggests that about 1 in 3,000 men and about 1 in 6,000 women in the general population have fragile X-associated tremor/ataxia syndrome (FXTAS), which could be a common neurodegenerative disorder among the general population; however, more studies are necessary to define the incidence and prevalence of FXTAS. The clinical recommendations for testing of *FMRI* mutation have been expanded after the description of premutation disorders and in this review we provide recommendations of offering testing for adults and will discuss the recent clinical, radiological, molecular and treatment research in FXTAS.

*Address correspondence to:

Dr. Reymundo Lozano, UC Davis MIND Institute and Department of Pediatrics, UC Davis Medical Center, Sacramento, CA, USA.

E-mail: reymundo.lozano@ucdmc.ucdavis.edu

2. Clinical indications for FXS genetic testing in adults

The family history is crucial to determine whether

there is an X-linked inheritance pattern of intellectual disability (ID) which would be typical for fragile X syndrome. However clinical suspicion of a premutation disorder should also be a consideration for *FMRI* DNA testing. The American Academy of Pediatrics and the American College of Medical Genetics currently recommends *FMRI* DNA testing for all children and adults with undiagnosed developmental delay/ID (12) and/or autism (ASD) (13). The American College of Obstetricians and Gynecologist (ACOG) also recommends testing in women with a family history of fragile X-related disorders, such as, unexplained ID/developmental delay, ASD or primary ovarian insufficiency (POI). In order to expand the screening criteria and to capture more premutation carriers the ACOG also recommends offering testing to all women who request fragile X carrier screening regardless of their personal and family history and also recommends to offer prenatal testing by amniocentesis or CVS to a known pregnant PMC (14). We also recommend considering genetic testing when there is personal medical history of unexplained late onset dementia or parkinsonism with any other associated premutation disorder and to consider testing in individuals with family history of a member with unexplained POI and mood/anxiety disorder, fibromyalgia and mood/anxiety disorder, and undiagnosed dementia or parkinsonism and anxiety/mood disorder (Table 1).

3. FXTAS

Although the prevalence of FXTAS in the general population is uncertain, FXTAS occurs in approximately 40-45% of male PMC and 8-16% of female PMC over the age of 50 (15-18). The common features of FXTAS are cognitive decline, autonomic dysfunction, neuropathy, and psychiatric features such as anxiety, depression, and apathy (16,19-21). Impairments in executive function abilities including working memory, inhibitory control and visuospatial processing begin as early as middle adulthood, and progressively worsen with increasing age (22-26). Subsequently dementia develops in approximately 50% of male PMC and autonomic dysfunction which is thought to be a consequence of involvement of the peripheral nervous system in common (27,28). Premutation-associated

psychiatric problems are common in adulthood but these problems can worsen before the appearance of tremor and ataxia (20,29-31). The increased lifetime prevalence of mood disorders (65%) and of anxiety disorders (52%) in individuals with FXTAS is greater than in those PMC without the FXTAS (20,31). The age of onset of FXTAS is typically between the ages of 60 and 65 years; the mean age of onset is 62 years (32,33). However, the chance of developing core symptoms of FXTAS (tremor and ataxia) increases with age. From age 50-59 the prevalence of FXTAS in males is 17 percent, from age 60-69 about 38 percent, from age 70-79 about 47 percent, and in males over 80 years old, about 75 percent (32).

Men are more frequently diagnosed with a definite diagnosis of FXTAS compared to women (34). A previous longitudinal study of progression of tremor and ataxia in 55 male PMCs showed that tremor usually occurs first, with median onset of ~ 60 years of age (35). After the tremor onset, the median onset of ataxia was 2 years later; onset of falls was 6 years later; dependence on a walking aid was 15 years later; and death was 21 years later (35). The rate of progression of FXTAS varies and life expectancy is between 5 to 25 years after the onset of the symptoms (36).

FXTAS in females was initially reported in 2004 (37). FXTAS is less common and shows a milder presentation in females because they have a normal X chromosome in addition to the *FMRI*-premutated X-chromosome (34). The proportion of normal *FMRI* alleles on the active X chromosome (activation ratio) is thought to modulate the phenotypic severity in females (38); however, double heterozygous female have been reported and they seem to have a similar clinical presentation to heterozygous females (39,40). Dementia was found in 21-50% males with FXTAS (32,36). In females with FXTAS, however, dementia is far less common (36,37) and it has been reported in only a few cases (41-45). Females with FXTAS may also exhibit parkinsonism, although at a lower rate than in males with FXTAS (34). There are associated symptoms in females with FXTAS that usually do not occur in males, including thyroid disorders, fibromyalgia and chronic muscle pain (46,47). Conversion disorder has also been reported in a PMC female (48). Migraine headache were reported in a higher rate in females (54.2%) when

Table 1. Guidelines to recommend and offer FXS genetic testing

	Recommend Genetic Testing	Offer Genetics Testing
Women	<ul style="list-style-type: none"> • Premature ovarian insufficiency • Women who request fragile X prenatal carrier screening 	<ul style="list-style-type: none"> • Family history of POI and mood/anxiety disorder • Family history fibromyalgia and mood/anxiety disorder • Prenatal testing by amniocentesis or CVS for known PMC
All Adults	<ul style="list-style-type: none"> • Intellectual Disability (ID) • Autism Spectrum Disorder (ASD) • Family history of ID or ASD • Family history of FXS • Unexplained late onset tremor and ataxia 	<ul style="list-style-type: none"> • Late onset dementia associated other premutation disorders • Family history of undiagnosed dementia or parkinsonism associated other premutation disorders • "MCP sign" or white matter lesions in the cerebral white matter on MRI

compared with males (26.8%) with the permutation (49). Immune mediated disorders have been described at a higher rate in females with FXTAS 72.73% compared with 46.54% female carriers and both rates are higher than published controls (47). Females with FXTAS also have a lower frequency of tremor compared to males with FXTAS (34).

4. Radiological findings

Cerebral magnetic resonance imaging (MRI) in patients with FXTAS shows global brain atrophy, enlargement of ventricular volume, white matter disease and heightened signal intensity with lesions in the middle cerebellar peduncles (50-53) (Figure 1). The middle cerebellar peduncle (MCP) sign presents as white matter hyperintensities in the middle cerebellar peduncles, and it is a cardinal radiological sign for the diagnosis of FXTAS (16). The MCP sign includes fronto-cerebellar tracts connecting to orbitofrontal and dorsolateral

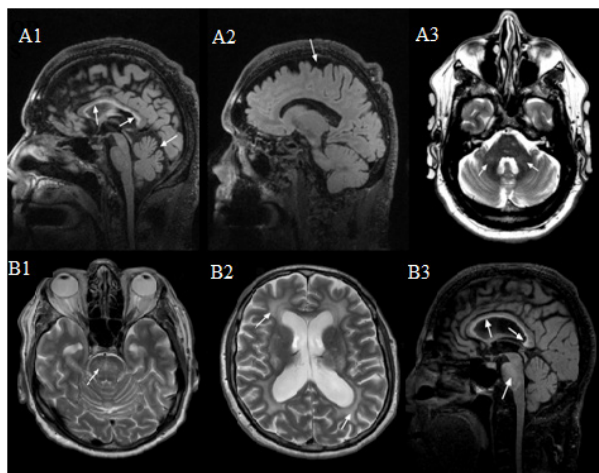


Figure 1. MRI features of FXTAS. (A1) Moderately thin truncus of the corpus callosum with severe increased signal intensity in both the truncus and the splenium, and moderate cerebellar and cerebral (A2) volume loss. (A3) Mild white matter changes in the middle cerebellar peduncles (MCPs). (B1) Severe increased T2 signal intensity in the pons (can also be seen in B3). (B2) Severe diffuse increased T2 signal intensity in the deep white matter of the cerebrum, as well as periventricular. (B3) Moderately thin truncus of the corpus callosum with severe increased T2 signal intensity in both the truncus and the splenium.

Table 2. Current diagnostic criteria of FXTAS

Molecular: *FMR1* gray mutation, premutation or full mutation (Mandatory for all categories).

Diagnostic	Definite	one major clinical + one major radiological or one major clinical + intranuclear inclusions (postmortem)
	Probable	two major clinical or one minor clinical + one major radiological
	Possible	one major clinical + one minor radiological
Clinical	Major	intention tremor; cerebellar ataxia
	Minor	Parkinsonism; moderate to severe short term or executive function deficits; neuropathy
Radiological	Major	MCPs; MRI white matter lesions in splenium of the corpus callosum (or postmortem intranuclear inclusions)
	Minor	MRI lesions in the cerebral white matter; moderate to severe generalized atrophy

MCPs; white matter lesions in middle cerebellar peduncle sign.

prefrontal cortices that are critical for cognitive control (54). Correspondingly, those with FXTAS and the MCP sign are likely to have more severe cognitive deficits and a longer history of symptoms than those without the MCP sign (55). Asymptomatic *FMR1* premutation carriers show white matter alterations (demyelination and axonal damage) of the afferent projections of the MCPs and superior cerebellar peduncles (53,56,57), which may be the earliest neuroanatomical marker of the onset of cognitive and motor symptoms associated with FXTAS (58).

Other common neuroimaging signs of FXTAS include white matter hyperintensities in the pons, insula, splenium of the corpus callosum, and periventricular region (59,60). T2-weighted and FLAIR corpus callosum splenium (CCS) hyperintensity was as frequent (68%) as MCP hyperintensities (64%) and it may be a marker of severe disease progression in FXTAS (34). Women with FXTAS have less white matter disease and brain atrophy on MRI, as well as less dementia in late-stages of FXTAS than men with FXTAS (36,50). The MCP sign was demonstrated in 13% of females compared with 58% of males with FXTAS (50). Corpus Callosum Splenium (CCS) hyperintensities were present in 50% of females versus 72% males (34).

5. Diagnosis and clinical severity stage of FXTAS

The FXTAS diagnostic revised criteria are presented in Table 2 (16,17). The clinical severity of FXTAS is estimated by using an empirical staging system, which incorporates the motor signs of FXTAS. The system gives an indication of the impact of motor aspects of the disease on activities of daily living as described in Table 3.

6. Molecular mechanisms of FXTAS

PMC were initially described with normal *FMRP* levels (61-64). However new molecular techniques led Tassone and colleagues (2000) (65) to the identification of increased *FMR1* mRNA levels; Kenneson and colleagues (2001) (66) also demonstrated low *FMRP* levels in PMC. Current research shows that as the premutation increases from 55 to 200, particularly

Table 3. Clinical staging of FXTAS

Stage	Clinical Description
0	Normal functions
1	Subtle or questionable signs such as subtle tremor or mild balance problems and no interference with ADLs
2	Clear tremor and/or balance problems and minor interference with ADLs
3	Moderate tremor and/or balance problems and occasional falls and significant interference with ADLs
4	Severe tremor and/or balance problems with at least intermittent use of a cane or a walker
5	The use of a wheelchair on a daily basis
6	Bedridden

ADL: activities of daily living.

more than 110 CGG repeats, the level of *FMRI* mRNA increases and the levels of FMRP start to decline (67,68). The CGG repeat size also correlates with the age of onset and the age of death from FXTAS (38,67). The elevated level of mRNA in PMCs led to the hypothesis of "*FMRI* mRNA toxicity" in FXTAS, however the causative mechanism of increase transcription by the CGG repeat remains unclear as well as the mechanism of neuronal toxicity by the accumulation of the *FMRI* mRNA. There are a few suggested pathological models including; "RNA toxicity"; a sequestration model which suggests that the RNA expanded CGG repeats are pathogenic by toxic sequestration of crucial transcriptional proteins (DROSHA-DGCR8, hnRNP A2/B1, SAM68, Pura, Rm62, and CUGBP1) (69-72); a non-canonical translation the CGG repeats which may result in the expression of toxic polyglycine products (73,74); and lastly the presence of antisense *FMRI* transcription which may lead to toxicity by antisense transcripts products (75).

7. Neuropathology and neurobiology of FXTAS

The neuronal toxicity is thought to be led by the formation of pathognomonic eosinophilic and ubiquitin-positive intranuclear inclusions in neurons and astrocytes throughout the brain, peripheral nervous system and other organs such as the adrenals, thyroid, heart, Leydig cells and pancreas (28,76-78). Other findings include mild brain atrophy and involvement of the cerebellum (MPC sign), loss of Purkinje neuronal cells, spongiosis of the deep cerebellar white matter, Bergman gliosis, and swollen axons (51,77). Neurons of heterozygous female mice with the premutation showed shorter dendritic lengths and fewer branches between 7 and 21 days compared with wild-type (WT) littermates, display lower viability, and express elevated stress protein levels (79). Furthermore altered embryonic neocortical development (80) and abnormal spontaneous clustered calcium bursts (81,82) with glutamate hyper-responsiveness have been described (81); thus suggesting a clear state of neuronal vulnerability.

Mitochondrial abnormalities have also been found in PMC (83,84) and recently a decreased immune responses and immune dysregulation in both humans

and mice with the premutation were described (85). It is unknown how the premutation alters mitochondrial and immunological responses, and if these abnormalities contribute to FXTAS and other associations found in PMC, such as, autoimmune and rheumatologic disorders (47).

8. Treatment of FXTAS

There are as yet no effective targeted therapies for the treatment of FXTAS; however there are many medications that have been used to ameliorate some of the symptoms associated to FXTAS. However the use of these medications rely on very few small trials and case studies that showed improvements only in some individuals (86,87). The only clinical targeted trial for FXTAS utilized memantine (NMDA receptor antagonist, FDA approved for treatment of moderate to severe Alzheimer's disease since 2003). Memantine was thought to selectively block the excitotoxic effects associated with abnormal transmission of glutamate while allowing for the physiological transmission associated with normal cell functioning. In this randomized, double-blind, placebo-controlled trial, 94 individuals aged 34-80 years with probable or possible FXTAS diagnosis and clinical stages 1-5 were enrolled for one year. Primary outcome measures were the Behavioral Dyscontrol Scale (BDS) score and CATSYS intention tremor severity. Intention-to-treat analysis showed no improvement with respect to intention tremor severity nor BDS scores (88). However of those (94 participants) 41 completed longitudinal ERP studies (20 placebo/21 memantine group) and the use of this compound showed improvements on cued-recall memory and N400 repetition effect amplitude; thus suggest that the treatment may have benefits on verbal memory (88). More frequent mild adverse events were observed in the placebo group, while more frequent moderate adverse events occurred in the memantine group and these included dizziness, headache and constipation amongst others. As mentioned before other treatments are directed to symptom reduction. For anxiety and depression selective serotonin and selective norepinephrine reuptake inhibitors are effective (5,86) as well as psychotherapy (31). Atypical antipsychotics are effective in individuals with psychosis and agitation

(89). Propranolol and primidone may improve tremor (86,87,90). Deep brain stimulation has shown benefits for tremor and in few cases for ataxia (91); however the general outcome for FXTAS patients was poor (92). As previously mentioned the premutation causes neuronal susceptibility and therefore other treatments for PMC focus on preventive measures, such as, avoidance of toxins including smoking alcohol and some types of anesthesia, healthy diet and vitamins/antioxidants supplementation, exercise and cognitive training, and stress reduction (93).

9. Current research on FXTAS

Phenotype studies aim to determine early signs of disease for early diagnosis and treatment as well as to determine timing and reversibility of the pathological mechanism. A preliminary study shows that oculomotor inhibitory control impairments (measured by eye tracking) might precede FXTAS, and thus indicating elevated risk for motor impairment associated with FXTAS (94). Magnetic resonance imaging is useful for non-invasive testing; functional MRI for brain activation during cognitive tasks, and structural MRI for quantification of volume changes, morphometry, and white/gray matter integrity and connectivity. In fact, verbal working memory in male and female premutation carriers (95) has been associated with reduced activation in the right inferior frontal cortex and left premotor cortex in both asymptomatic premutation carriers and carriers with FXTAS. Reduced activation was found in right premotor/inferior frontal cortex in individuals with FXTAS. Individuals with FXTAS also showed diffuse gray matter loss most prominent in areas important for working memory, including prefrontal cortex, anterior cingulate cortex, and cerebellum (96). Molecular studies aim to determine the early molecular mechanisms that induce neurodegeneration including cellular stress and toxicity. The mechanism for inclusion formation and identification the intranuclear inclusions proteins are also a fertile area of research. Current targeted treatment research focuses on reversing the neurobiological abnormalities in FXTAS with pharmaceutical compounds (e.g. allopregnanolone) and other molecular mechanisms of disease modification (oligonucleotide-based therapies to reduce *FMRI* mRNA) as well as designing a mechanism that will allow blood-brain cross-transportation of pharmacological compounds.

Animal models for the fragile X premutation have been developed to understand the molecular mechanism of FXTAS (97). Mice models have shown increased *FMRI* mRNA levels, decreased FMRP levels and ubiquitin-positive intranuclear inclusions (98). In addition, mice models showed neurocognitive deficits in spatial and temporal memory processes, impaired motor performance, and anxiety traits (99). In order to

determine timing and reversibility of disease and their associate molecular mechanism, a doxycycline-inducible premutation mouse has been created (R. Hukema, Abstracts of the 1st Premutation Meeting, Perugia, Italy, 2013). Animal models are crucial in the testing of preclinical therapies, for instance the acute administration of the neurosteroid allopregnanolone mitigated cluster burst firing in mouse hippocampal premutation-neurons and identified allopregnanolone as a potential targeted treatment for premutation disorders (100).

10. FXTAS

The identification of the *FMRI* gene has led to characterization of risk alleles and recently there are a variety of disorders associated with the premutation in children and adults. Although FXTAS is described to occur in premutation carriers only, recent reports identified FXTAS in individuals with grey zone/intermediate alleles (101,102), as well as in individuals with unmethylated full-mutation alleles (103) and in a few patients with full-mutation/premutation mosaicism (104). These findings increase the number of patients that are at risk for FXTAS with elevated *FMRI* mRNA besides only those with the premutation. The description of FXTAS as an intractable disorder, has led to expansion of recommendations for genetic testing in adults which in turn have caused ethical concerns for the identification of individuals at risk of FXTAS. These is a concern especially in males with the suspicion of the premutation because males do not have increased risk of having children with fragile X syndrome, but have about a 40% chances to develop FXTAS, if they are determined to be premutation carriers. However, the documentation of the premutation is helpful for both males and females because these individuals can be treated for many of the childhood and adult problems related to the premutation such as anxiety, depression, ADHD, hypertension, hypothyroidism, fibromyalgia, sleep apnea, and can be counseled to avoid toxicity from the environment that has the potential to bring on FXTAS at an earlier age. The identification of radiological signs of FXTAS is used by clinicians to make a clinical diagnosis of FXTAS; however, the phenotypic variability and progression of FXTAS should be taken in consideration as many adults will not meet all clinical criteria until advanced age, particularly females. There are also radiological and clinical gender variations, while males are more prone to develop dementia, females are more likely to develop other autoimmune-related disorders. The phenotypic variability of the premutation is partially explain by CGG expansion size, *FMRI* mRNA levels, decrease FMRP and mosaicism; however, other mechanisms are now being consider including protein synthesis alterations, non-AUG translation, and antisense transcription, as well as, additional

genomic variants and environmental exposures (5). Further genotype to phenotype studies are necessary to determine the relative contribution of these pathological processes in this complex disorder. Many FDA approved medications have shown to improve some of the symptoms of FXTAS; however there are limited clinical trials and none that can prove the efficacy of these treatments. It is crucial to undertake further clinical trials of drugs that anecdotally have shown positive results in individuals with FXTAS. There has been only one targeted clinical trial for FXTAS and there is an urgent need to identify more compounds that target the pathogenesis of FXTAS, which in theory may reverse, treat or prevent the development of FXTAS.

Acknowledgements

This work was supported by the National Institute on Aging of the National Institutes of Health (P30AG043097) and NICHD diversity supplement (HD036071). RL and ZM declare no competing financial interests.

References

- Cronister A, Schreiner R, Wittenberger M, Amiri K, Harris K, Hagerman RJ. Heterozygous fragile X female: Historical, physical, cognitive, and cytogenetic features. *Am J Med Genet.* 1991; 38:269-274.
- Mazzocco MM, Pennington BF, Hagerman RJ. The neurocognitive phenotype of female carriers of fragile X: Additional evidence for specificity. *J Dev Behav Pediatr.* 1993; 14:328-335.
- Reiss AL, Freund L, Abrams MT, Boehm C, Kazazian H. Neurobehavioral effects of the fragile X premutation in adult women: A controlled study. *Am J Hum Genet.* 1993; 52:884-894.
- Rousseau F, Heitz D, Tarleton J, *et al.* A multicenter study on genotype-phenotype correlations in the fragile X syndrome, using direct diagnosis with probe StB12.3: The first 2,253 cases. *Am J Med Genet.* 1994; 55:225-237.
- Hagerman R, Hagerman P. Advances in clinical and molecular understanding of the *FMRI* premutation and fragile X-associated tremor/ataxia syndrome. *Lancet Neurol.* 2013; 12:786-798.
- Dombrowski C, Levesque S, Morel ML, Rouillard P, Morgan K, Rousseau F. Premutation and intermediate-size *FMRI* alleles in 10572 males from the general population: Loss of an AGG interruption is a late event in the generation of fragile X syndrome alleles. *Hum Mol Genet.* 2002; 11:371-378.
- Toledano-Alhadeff H, Basel-Vanagaite L, Magal N, Davidov B, Ehrlich S, Drasinover V, Taub E, Halpern GJ, Ginott N, Shohat M. Fragile-X carrier screening and the prevalence of premutation and full-mutation carriers in Israel. *Am J Hum Genet.* 2001; 69:351-360.
- Dawson AJ, Chodirker BN, Chudley AE. Frequency of *FMRI* premutations in a consecutive newborn population by PCR screening of Guthrie blood spots. *Biochem Mol Med.* 1995; 56:63-69.
- Rousseau F, Rouillard P, Morel ML, Khandjian EW, Morgan K. Prevalence of carriers of premutation-size alleles of the *FMRI* gene – and implications for the population genetics of the fragile X syndrome. *Am J Med Genet.* 1995; 57:1006-1018.
- Fernandez-Carvajal I, Walichiewicz P, Xiaosen X, Pan R, Hagerman PJ, Tassone F. Screening for expanded alleles of the *FMRI* gene in blood spots from newborn males in a Spanish population. *J Mol Diagn.* 2009; 11:324-329.
- Hagerman PJ. The fragile X prevalence paradox. *J Med Genet.* 2008; 45:498-499.
- Monaghan KG, Lyon E, Spector EB. ACMG Standards and Guidelines for fragile X testing: A revision to the disease-specific supplements to the Standards and Guidelines for Clinical Genetics Laboratories of the American College of Medical Genetics and Genomics. *Genet Med.* 2013; 15:575-586.
- Schaefer GB, Mendelsohn NJ. Clinical genetics evaluation in identifying the etiology of autism spectrum disorders: 2013 guideline revisions. *Genet Med.* 2013; 15:399-407.
- ACOG Committee Opinion No. 469: Carrier screening for fragile X syndrome. *Obstet Gynecol.* 2010; 116:1008-1010.
- Hagerman RJ, Leehey M, Heinrichs W, Tassone F, Wilson R, Hills J, Grigsby J, Gage B, Hagerman PJ. Intention tremor, parkinsonism, and generalized brain atrophy in male carriers of fragile X. *Neurology.* 2001; 57:127-130.
- Jacquemont S, Hagerman RJ, Leehey M, *et al.* Fragile X premutation tremor/ataxia syndrome: Molecular, clinical, and neuroimaging correlates. *Am J Med Genet.* 2003; 72:869-878.
- Berry-Kravis E, Abrams L, Coffey SM, *et al.* Fragile X-associated tremor/ataxia syndrome: Clinical features, genetics, and testing guidelines. *Mov Disord.* 2007; 22:2018-2030, quiz 2140.
- Tassone F, Adams J, Berry-Kravis EM, Cohen SS, Brusco A, Leehey MA, Li L, Hagerman RJ, Hagerman PJ. CGG repeat length correlates with age of onset of motor signs of the fragile X-associated tremor/ataxia syndrome (FXTAS). *Am J Med Genet B Neuropsychiatr Genet.* 2007; 144B:566-569.
- Amiri K, Hagerman RJ, Hagerman PJ. Fragile X-associated tremor/ataxia syndrome: An aging face of the fragile X gene. *Arch Neurol.* 2008; 65:19-25.
- Bourgeois JA, Seritan AL, Casillas EM, Hessler D, Schneider A, Yang Y, Kaur I, Cogswell JB, Nguyen DV, Hagerman RJ. Lifetime prevalence of mood and anxiety disorders in fragile X premutation carriers. *J Clin Psychiatry.* 2011; 72:175-182.
- Sevin M, Kutalik Z, Bergman S, Vercelletto M, Renou P, Lamy E, Vingerhoets FJ, Di Virgilio G, Boisseau P, Bezieau S, Pasquier L, Rival JM, Beckmann JS, Damier P, Jacquemont S. Penetrance of marked cognitive impairment in older male carriers of the *FMRI* gene premutation. *J Med Genet.* 2009; 46:818-824.
- Cornish KM, Li L, Kogan CS, Jacquemont S, Turk J, Dalton A, Hagerman RJ, Hagerman PJ. Age-dependent cognitive changes in carriers of the fragile X syndrome. *Cortex.* 2008; 44:628-636.
- Cornish KM, Kogan CS, Li L, Turk J, Jacquemont S, Hagerman RJ. Lifespan changes in working memory in fragile X premutation males. *Brain Cogn.* 2009; 69:551-558.

24. Cornish KM, Hocking DR, Moss SA, Kogan CS. Selective executive markers of at-risk profiles associated with the fragile X premutation. *Neurology*. 2011; 77:618-622.
25. Hocking DR, Kogan CS, Cornish KM. Selective spatial processing deficits in an at-risk subgroup of the fragile X premutation. *Brain Cogn*. 2012; 79:39-44.
26. Grigsby J, Brega AG, Engle K, Leehey MA, Hagerman RJ, Tassone F, Hessler D, Hagerman PJ, Cogswell JB, Bennett RE, Cook K, Hall DA, Bounds LS, Paulich MJ, Reynolds A. Cognitive profile of fragile X premutation carriers with and without fragile X-associated tremor/ataxia syndrome. *Neuropsychology*. 2008; 22:48-60.
27. Gokden M, Al-Hinti JT, Harik SI. Peripheral nervous system pathology in fragile X tremor/ataxia syndrome (FXTAS). *Neuropathology*. 2009; 29:280-284.
28. Hunsaker MR, Greco CM, Spath MA, Smits AP, Navarro CS, Tassone F, Kros JM, Severijnen LA, Berry-Kravis EM, Berman RF, Hagerman PJ, Willemsen R, Hagerman RJ, Hukema RK. Widespread non-central nervous system organ pathology in fragile X premutation carriers with fragile X-associated tremor/ataxia syndrome and CGG knock-in mice. *Acta Neuropathol*. 2011; 122:467-479.
29. Roberts JE, Bailey DB Jr, Mankowski J, Ford A, Sideris J, Weisenfeld LA, Heath TM, Golden RN. Mood and anxiety disorders in females with the *FMR1* premutation. *Am J Med Genet B Neuropsychiatr Genet*. 2009; 150B:130-139.
30. Seritan AL, Bourgeois JA, Schneider A, Mu Y, Hagerman RJ, Nguyen DV. Ages of Onset of Mood and Anxiety Disorders in Fragile X Premutation Carriers. *Curr Psychiatry Rev*. 2013; 9:65-71.
31. Seritan AL, Ortigas M, Seritan S, Bourgeois JA, Hagerman RJ. Psychiatric Disorders Associated with FXTAS. *Curr Psychiatry Rev*. 2013; 9:59-64.
32. Jacquemont S, Hagerman RJ, Leehey MA, *et al*. Penetrance of the fragile X-associated tremor/ataxia syndrome in a premutation carrier population. *JAMA*. 2004; 291:460-469.
33. Li Y, Jin P. RNA-mediated neurodegeneration in fragile X-associated tremor/ataxia syndrome. *Brain Res*. 2012; 1462:112-117.
34. Apartis E, Blancher A, Meissner WG, *et al*. FXTAS: New insights and the need for revised diagnostic criteria. *Neurology*. 2012; 79:1898-1907.
35. Leehey MA, Berry-Kravis E, Min SJ, *et al*. Progression of tremor and ataxia in male carriers of the *FMR1* premutation. *Mov Disord*. 2007; 22:203-206.
36. Seritan AL, Nguyen DV, Farias ST, Hinton L, Grigsby J, Bourgeois JA, Hagerman RJ. Dementia in fragile X-associated tremor/ataxia syndrome (FXTAS): Comparison with Alzheimer's disease. *Am J Med Genet B Neuropsychiatr Genet*. 2008; 147B:1138-1144.
37. Hagerman RJ, Leavitt BR, Farzin F, *et al*. Fragile X-associated tremor/ataxia syndrome (FXTAS) in females with the *FMR1* premutation. *Am J Hum Genet*. 2004; 74:1051-1056.
38. Leehey MA, Berry-Kravis E, Goetz CG, *et al*. *FMR1* CGG repeat length predicts motor dysfunction in premutation carriers. *Neurology*. 2008; 70:1397-1402.
39. Sorensen PL, Basuta K, Mendoza-Morales G, Gane LW, Schneider A, Hagerman R, Tassone F. A fragile X sibship from a consanguineous family with a compound heterozygous female and partially methylated full mutation male. *Am J Med Genet A*. 2012; 158A:1221-1224.
40. Basuta K, Lozano R, Schneider A, Yrigollen CM, Hessler D, Hagerman RJ, Tassone F. A family with two female siblings with compound heterozygous *FMR1* premutation alleles. *Clinical genetics*. 2014; 85:458-463.
41. Rodriguez-Revenga L, Madrigal I, Pagonabarraga J, Xuncla M, Badenas C, Kulisevsky J, Gomez B, Mila M. Penetrance of *FMR1* premutation associated pathologies in fragile X syndrome families. *Eur J Hum Genet*. 2009; 17:1359-1362.
42. Al-Hinti JT, Nagan N, Harik SI. Fragile X premutation in a woman with cognitive impairment, tremor, and history of premature ovarian failure. *Alzheimer Dis Assoc Disord*. 2007; 21:262-264.
43. Karmon Y, Gadoth N. Fragile X associated tremor/ataxia syndrome (FXTAS) with dementia in a female harbouring *FMR1* premutation. *J Neurol Neurosurg Psychiatry*. 2008; 79:738-739.
44. Yachnis AT, Roth HL, Heilman KM. Fragile X dementia Parkinsonism Syndrome (FXDPS). *Cogn Behav Neurol*. 2010; 23:39-43.
45. Tassone F, Greco CM, Hunsaker MR, Seritan AL, Berman RF, Gane LW, Jacquemont S, Basuta K, Jin LW, Hagerman PJ, Hagerman RJ. Neuropathological, clinical and molecular pathology in female fragile X premutation carriers with and without FXTAS. *Genes Brain Behav*. 2012; 11:577-585.
46. Coffey SM, Cook K, Tartaglia N, Tassone F, Nguyen DV, Pan R, Bronsky HE, Yuhas J, Borodyanskaya M, Grigsby J, Doerflinger M, Hagerman PJ, Hagerman RJ. Expanded clinical phenotype of women with the *FMR1* premutation. *Am J Med Genet A*. 2008; 146A:1009-1016.
47. Winarni TI, Chonchaiya W, Sumekar TA, Ashwood P, Morales GM, Tassone F, Nguyen DV, Faradz SM, Van de Water J, Cook K, Hamlin A, Mu Y, Hagerman PJ, Hagerman RJ. Immune-mediated disorders among women carriers of fragile X premutation alleles. *Am J Med Genet A*. 2012; 158A:2473-2481.
48. Seritan AL, Schneider A, Olichney JM, Leehey MA, Akins RS, Hagerman RJ. Conversion disorder in women with the *FMR1* premutation. *Am J Med Genet A*. 2009; 149A:2501-2506.
49. Au J, Akins RS, Berkowitz-Sutherland L, Tang HT, Chen Y, Boyd A, Tassone F, Nguyen DV, Hagerman R. Prevalence and risk of migraine headaches in adult fragile X premutation carriers. *Clin Genet*. 2013; 84:546-551.
50. Adams JS, Adams PE, Nguyen D, Brunberg JA, Tassone F, Zhang W, Koldewyn K, Rivera SM, Grigsby J, Zhang L, DeCarli C, Hagerman PJ, Hagerman RJ. Volumetric brain changes in females with fragile X-associated tremor/ataxia syndrome (FXTAS). *Neurology*. 2007; 69:851-859.
51. Brunberg JA, Jacquemont S, Hagerman RJ, Berry-Kravis EM, Grigsby J, Leehey MA, Tassone F, Brown WT, Greco CM, Hagerman PJ. Fragile X premutation carriers: Characteristic MR imaging findings of adult male patients with progressive cerebellar and cognitive dysfunction. *AJNR Am J Neuroradiol*. 2002; 23:1757-1766.
52. Peters N, Kamm C, Asmus F, Holinski-Feder E, Kraft E, Dichgans M, Bruning R, Gasser T, Botzel K. Intrafamilial variability in fragile X-associated tremor/ataxia syndrome. *Mov Disord*. 2006; 21:98-102.
53. Hashimoto R, Srivastava S, Tassone F, Hagerman

- RJ, Rivera SM. Diffusion tensor imaging in male premutation carriers of the fragile X mental retardation gene. *Mov Disord*. 2011; 26:1329-1336.
54. Kamali A, Kramer LA, Frye RE, Butler IJ, Hasan KM. Diffusion tensor tractography of the human brain cortico-ponto-cerebellar pathways: A quantitative preliminary study. *J Magn Reson Imaging*. 2010; 32:809-817.
 55. Juncos JL, Lazarus JT, Graves-Allen E, Shubeck L, Rusin M, Novak G, Hamilton D, Rohr J, Sherman SL. New clinical findings in the fragile X-associated tremor ataxia syndrome (FXTAS). *Neurogenetics*. 2011; 12:123-135.
 56. Battistella G, Niederhauser J, Fornari E, Hippolyte L, Gronchi Perrin A, Lesca G, Forzano F, Hagmann P, Vingerhoets FJ, Draganski B, Maeder P, Jacquemont S. Brain structure in asymptomatic *FMRI* premutation carriers at risk for fragile X-associated tremor/ataxia syndrome. *Neurobiol Aging*. 2013; 34:1700-1707.
 57. Wang JY, Hessl DH, Hagerman RJ, Tassone F, Rivera SM. Age-dependent structural connectivity effects in fragile X premutation. *Arch Neurol*. 2012; 69:482-489.
 58. Kraan CM, Hocking DR, Georgiou-Karistianis N, Metcalfe SA, Archibald AD, Fielding J, Trollor J, Bradshaw JL, Cohen J, Cornish KM. Cognitive-motor interference during postural control indicates at-risk cerebellar profiles in females with the *FMRI* premutation. *Behav Brain Res*. 2013; 253:329-336.
 59. Loesch DZ, Kotschet K, Trost N, Greco CM, Kinsella G, Slater HR, Venn A, Horne M. White matter changes in basis pontis in small expansion *FMRI* allele carriers with parkinsonism. *Am J Med Genet B Neuropsychiatr Genet*. 2011; 156B:502-506.
 60. Moris G, Arias M, Lopez MV, Alvarez V. Hyperintensity in the basis pontis: A typical neuroradiological findings in a woman with FXTAS. *Mov Disord*. 2010; 25:649-650.
 61. Devys D, Lutz Y, Rouyer N, Bellocq JP, Mandel JL. The FMR-1 protein is cytoplasmic, most abundant in neurons and appears normal in carriers of a fragile X premutation. *Nat Genet*. 1993; 4:335-340.
 62. Feng Y, Lakkis L, Devys D, Warren ST. Quantitative comparison of *FMRI* gene expression in normal and premutation alleles. *American journal of human genetics*. 1995; 56:106-113.
 63. Pieretti M, Zhang FP, Fu YH, Warren ST, Oostra BA, Caskey CT, Nelson DL. Absence of expression of the *FMR-1* gene in fragile X syndrome. *Cell*. 1991; 66:817-822.
 64. Siomi H, Siomi MC, Nussbaum RL, Dreyfuss G. The protein product of the fragile X gene, *FMRI*, has characteristics of an RNA-binding protein. *Cell*. 1993; 74:291-298.
 65. Tassone F, Hagerman RJ, Taylor AK, Gane LW, Godfrey TE, Hagerman PJ. Elevated levels of *FMRI* mRNA in carrier males: A new mechanism of involvement in the fragile-X syndrome. *Am J Hum Genet*. 2000; 66:6-15.
 66. Kenneson A, Zhang F, Hagedorn CH, Warren ST. Reduced FMRP and increased *FMRI* transcription is proportionally associated with CGG repeat number in intermediate-length and premutation carriers. *Hum Mol Genet*. 2001; 10:1449-1454.
 67. Ludwig AL, Espinal GM, Pretto DI, Jamal AL, Arque G, Tassone F, Berman RF, Hagerman PJ. CNS expression of murine fragile X protein (FMRP) as a function of CGG-repeat size. *Hum Mol Genet*. 2014; 23:3228-3238.
 68. Pretto DI, Mendoza-Morales G, Lo J, Cao R, Hadd A, Latham GJ, Durbin-Johnson B, Hagerman R, Tassone F. CGG allele size somatic mosaicism and methylation in *FMRI* premutation alleles. *J Med Genet*. 2014; 51:309-318.
 69. Sofola OA, Jin P, Qin Y, Duan R, Liu H, de Haro M, Nelson DL, Botas J. RNA-binding proteins hnRNP A2/B1 and CUGBP1 suppress fragile X CGG premutation repeat-induced neurodegeneration in a *Drosophila* model of FXTAS. *Neuron*. 2007; 55:565-571.
 70. Jin P, Duan R, Qurashi A, Qin Y, Tian D, Rosser TC, Liu H, Feng Y, Warren ST. Pur alpha binds to rCGG repeats and modulates repeat-mediated neurodegeneration in a *Drosophila* model of fragile X tremor/ataxia syndrome. *Neuron*. 2007; 55:556-564.
 71. Sellier C, Freyermuth F, Tabet R, et al. Sequestration of DROSHA and DGCR8 by expanded CGG RNA repeats alters microRNA processing in fragile X-associated tremor/ataxia syndrome. *Cell rep*. 2013; 3:869-880.
 72. Qurashi A, Li W, Zhou JY, Peng J, Jin P. Nuclear accumulation of stress response mRNAs contributes to the neurodegeneration caused by Fragile X premutation rCGG repeats. *PLoS genetics*. 2011; 7:e1002102.
 73. Reddy K, Pearson CE. RAN translation: Fragile X in the running. *Neuron*. 2013; 78:405-408.
 74. Todd PK, Oh SY, Krans A, et al. CGG repeat-associated translation mediates neurodegeneration in fragile X tremor ataxia syndrome. *Neuron*. 2013; 78:440-455.
 75. Ladd PD, Smith LE, Rabaia NA, Moore JM, Georges SA, Hansen RS, Hagerman RJ, Tassone F, Tapscott SJ, Filippova GN. An antisense transcript spanning the CGG repeat region of *FMRI* is upregulated in premutation carriers but silenced in full mutation individuals. *Hum Mol Genet*. 2007; 16:3174-3187.
 76. Greco CM, Hagerman RJ, Tassone F, Chudley AE, Del Bigio MR, Jacquemont S, Leehey M, Hagerman PJ. Neuronal intranuclear inclusions in a new cerebellar tremor/ataxia syndrome among fragile X carriers. *Brain*. 2002; 125:1760-1771.
 77. Greco CM, Berman RF, Martin RM, et al. Neuropathology of fragile X-associated tremor/ataxia syndrome (FXTAS). *Brain*. 2006; 129:243-255.
 78. Greco CM, Soontrapornchai K, Wirojanan J, Gould JE, Hagerman PJ, Hagerman RJ. Testicular and pituitary inclusion formation in fragile X associated tremor/ataxia syndrome. *J Urol*. 2007; 177:1434-1437.
 79. Chen Y, Tassone F, Berman RF, Hagerman PJ, Hagerman RJ, Willemsen R, Pessah IN. Murine hippocampal neurons expressing *FMRI* gene premutations show early developmental deficits and late degeneration. *Hum Mol Genet*. 2010; 19:196-208.
 80. Cunningham CL, Martinez Cerdeno V, Navarro Porras E, Prakash AN, Angelastro JM, Willemsen R, Hagerman PJ, Pessah IN, Berman RF, Noctor SC. Premutation CGG-repeat expansion of the *FMRI* gene impairs mouse neocortical development. *Hum Mol Genet*. 2011; 20:64-79.
 81. Liu J, Koscielska KA, Cao Z, Hulsizer S, Grace N, Mitchell G, Nacey C, Githinji J, McGee J, Garcia-Arocena D, Hagerman RJ, Nolte J, Pessah IN, Hagerman PJ. Signaling defects in iPSC-derived fragile X premutation neurons. *Hum Mol Genet*. 2012; 21:3795-3805.
 82. Cao Z, Hulsizer S, Cui Y, Pretto DL, Kim KH, Hagerman PJ, Tassone F, Pessah IN. Enhanced asynchronous Ca²⁺ oscillations associated with impaired glutamate transport

- in cortical astrocytes expressing *FMR1* gene premutation expansion. *J Biol Chem.* 2013; 288:13831-13841.
83. Ross-Inta C, Omanska-Klusek A, Wong S, Barrow C, Garcia-Arocena D, Iwahashi C, Berry-Kravis E, Hagerman RJ, Hagerman PJ, Giulivi C. Evidence of mitochondrial dysfunction in fragile X-associated tremor/ataxia syndrome. *Biochem J.* 2010; 429:545-552.
 84. Napoli E, Ross-Inta C, Wong S, Omanska-Klusek A, Barrow C, Iwahashi C, Garcia-Arocena D, Sakaguchi D, Berry-Kravis E, Hagerman R, Hagerman PJ, Giulivi C. Altered zinc transport disrupts mitochondrial protein processing/import in fragile X-associated tremor/ataxia syndrome. *Hum Mol Genet.* 2011; 20:3079-3092.
 85. Careaga M, Rose D, Tassone F, Berman RF, Hagerman R, Ashwood P. Immune dysregulation as a cause of autoinflammation in fragile X premutation carriers: Link between *FMR1* CGG repeat number and decreased cytokine responses. *PLoS One.* 2014; 9:e94475.
 86. Hagerman RJ, Hall DA, Coffey S, *et al.* Treatment of fragile X-associated tremor ataxia syndrome (FXTAS) and related neurological problems. *Clin Interv Aging.* 2008; 3:251-262.
 87. Leehey MA. Fragile X-associated tremor/ataxia syndrome: Clinical phenotype, diagnosis, and treatment. *J Investig Med.* 2009; 57:830-836.
 88. Yang JC, Niu YQ, Simon C, Seritan AL, Chen L, Schneider A, Moghaddam ST, Hagerman PJ, Hagerman RJ. Memantine Effects on verbal memory in fragile X-associated tremor/ataxia syndrome (FXTAS): A double-blind brain potential study. *Neuropsychopharmacology.* 2014; 39:2760-2768.
 89. Bourgeois J, Coffey S, Rivera SM, Hessel D, Gane LW, Tassone F, Greco C, Finucane B, Nelson L, Berry-Kravis E, Grigsby J, Hagerman PJ, Hagerman RJ. Fragile X premutation disorders – Expanding the psychiatric perspective. *J Clin Psychiatry.* 2009; 70:852-862.
 90. Hall DA, Berry-Kravis E, Hagerman RJ, Hagerman PJ, Rice CD, Leehey MA. Symptomatic treatment in the fragile X-associated tremor/ataxia syndrome. *Mov Disord.* 2006; 21:1741-1744.
 91. Hagerman J, Jamie SP, Ortigas M, Olichney J, Frysinger R, Harrison M, Cornman E, Danuta ZL, Richard GB, Peppard R, Zhang L, Shahlaie K. Case Series: Deep brain stimulation in patients with FXTAS. *Brain Disord Ther.* 2012; 1:2
 92. Oyama G, Thompson A, Foote KD, Limotai N, Abd-El-Barr M, Maling N, Malaty IA, Rodriguez RL, Subramony SH, Ashizawa T, Okun MS. Deep brain stimulation for tremor associated with underlying ataxia syndromes: A case series and discussion of issues. *Tremor Other Hyperkinet Mov (N Y).* 2014; 4:228.
 93. Polussa J, Schneider A, Hagerman R. Molecular advances leading to treatment implications for fragile X premutation carriers. *Brain Disord Ther.* 2014; 3:1000119.
 94. Wong LM, Goodrich-Hunsaker NJ, McLennan Y, Tassone F, Zhang M, Rivera SM, Simon TJ. Eye movements reveal impaired inhibitory control in adult male fragile X premutation carriers asymptomatic for FXTAS. *Neuropsychology.* 2014; 28:571-584.
 95. Hashimoto R, Backer KC, Tassone F, Hagerman RJ, Rivera SM. An fMRI study of the prefrontal activity during the performance of a working memory task in premutation carriers of the fragile X mental retardation 1 gene with and without fragile X-associated tremor/ataxia syndrome (FXTAS). *J Psychiatr Res.* 2011; 45:36-43.
 96. Hashimoto R, Javan AK, Tassone F, Hagerman RJ, Rivera SM. A voxel-based morphometry study of grey matter loss in fragile X-associated tremor/ataxia syndrome. *Brain.* 2011; 134:863-878.
 97. Berman RF, Buijsen RA, Usdin K, Pintado E, Kooy F, Pretto D, Pessah IN, Nelson DL, Zalewski Z, Charlet-Bergeurand N, Willemsen R, Hukema RK. Mouse models of the fragile X premutation and fragile X-associated tremor/ataxia syndrome. *J Neurodev Disord.* 2014; 6:25.
 98. Berman RF, Willemsen R. Mouse models of fragile X-associated tremor ataxia. *J Investig Med.* 2009; 57:837-841.
 99. Hunsaker MR, Wenzel HJ, Willemsen R, Berman RF. Progressive spatial processing deficits in a mouse model of the fragile X premutation. *Behav Neurosci.* 2009; 123:1315-1324.
 100. Cao Z, Hulsizer S, Tassone F, Tang HT, Hagerman RJ, Rogawski MA, Hagerman PJ, Pessah IN. Clustered burst firing in *FMR1* premutation hippocampal neurons: Amelioration with allopregnanolone. *Hum Mol Genet.* 2012; 21:2923-2935.
 101. Hall D, Tassone F, Klepitskaya O, Leehey M. Fragile X-associated tremor ataxia syndrome in *FMR1* gray zone allele carriers. *Mov Disord.* 2012; 27:296-300.
 102. Liu Y, Winarni TI, Zhang L, Tassone F, Hagerman RJ. Fragile X-associated tremor/ataxia syndrome (FXTAS) in grey zone carriers. *Clin Genet.* 2013; 84:74-77.
 103. Loesch DZ, Sherwell S, Kinsella G, Tassone F, Taylor A, Amor D, Sung S, Evans A. Fragile X-associated tremor/ataxia phenotype in a male carrier of unmethylated full mutation in the *FMR1* gene. *Clin Genet.* 2012; 82:88-92.
 104. Pretto DI, Hunsaker MR, Cunningham CL, Greco CM, Hagerman RJ, Noctor SC, Hall DA, Hagerman PJ, Tassone F. Intranuclear inclusions in a fragile X mosaic male. *Transl Neurodegener.* 2013; 2:10.

(Received October 21, 2014; Accepted November 30, 2014)