

Accessory lobes of the liver: A report of 3 cases and review of the literature

Chenglin Wang*, Lin Cheng, Ziqin Zhang, Tingting Xie, Heyu Ding, Qianhua Deng, Zhidong Yuan

Department of Medical Imaging, Peking University Shenzhen Hospital, Shenzhen, China.

Summary This article is about 3 cases of accessory lobes of the liver. Case One involved a pedunculated accessory lobe of the liver (ALL), Case Two involved a true ectopic liver, and Case Three involved a sessile accessory lobe of the liver. All 3 cases were diagnosed by computed tomography (CT) or magnetic resonance imaging (MRI) and confirmed by surgical and histological examination. The pertinent literature on accessory lobes of the liver is also reviewed.

Keywords: Accessory lobe of the liver (ALL), computed tomography (CT), magnetic resonance image (MRI)

1. Introduction

Accessory lobe of the liver (ALL) is congenital ectopic hepatic tissue mostly due to embryonic heteroplasia, though in rare instances an ALL may occur after trauma or surgery. There are two types of ALL: an accessory lobe joined to normal hepatic tissue and a lobe that is completely separate (1). An ALL, and especially a completely separate ALL, is rarely clinically and is difficult to diagnose before surgery, so it is easily missed or misdiagnosed. Hundal noted that from 1925 to 2006 there were 18 cases of an ALL diagnosed after surgery or biopsy (2). The current authors report 3 additional cases that were positive diagnosed by computed tomography (CT) and magnetic resonance image (MRI) and synthesized images.

2. Case report

2.1. Case One

Chest films for a 59-year-old female showed a mass in the lower right costophrenic angle with distinct margins and a uniform density. The mass was thought

to be a benign tumor in the pulmonary basal segment. An ultrasound was performed to differentiate the mass from a subphrenic mass. The exam showed a lesion occupying the right posterior lobe of the liver with indistinct margins, a uniform echo, and blood flow. This was thought to be a benign tumor possibly originating from the liver. Unenhanced MRI scan: T1-weighted imaging (T1WI) showed an irregular mass in the right posterior lobe of the liver, all of its margins were distinct except the inboard part. The mass had a homogeneous signal (Figure 1A). T2-weighted imaging (T2WI) showed that the mass had the same signal intensity as normal liver tissue and a homogenous signal; vascular opacities were apparent inside (Figure 1B). Coronal scanning showed distinct margins and a low signal line demarcating the mass from normal liver tissue (Figure 1C). Vertical scanning showed a mass connected to the right lobe by a stalk of tissue (Figure 1D). MRI diagnosis: Pedunculated ALL.

2.2. Case Two

A 20-year-old male visited the hospital due to coughing and a fever. Plain films showed an irregular mass in the right lower lung field; its margins were distinct and it had a uniform density, and there was a clear line demarcating it and normal liver tissue (Figure 2A). Enhanced scanning showed that the mass had the same degree of contrast enhancement as normal liver tissue

*Address correspondence to:

Dr. Chenglin Wang, Department of Medical Imaging, Peking University Shenzhen Hospital, No. 1120 Lianhua Road, Futian District, Shenzhen 518036, China.
E-mail: wcl13510331556@163.com

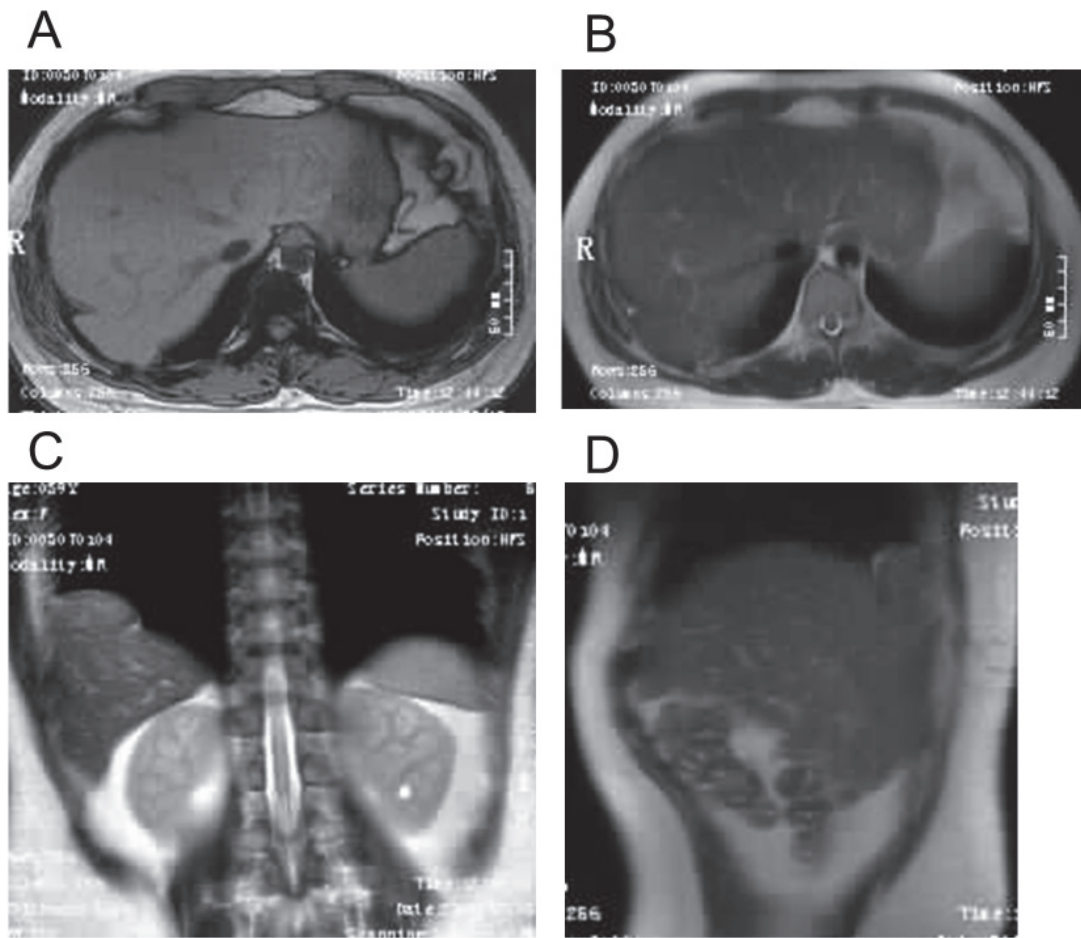


Figure 1. Case One. (A) T1WI showed a mass in the right posterior lobe of the liver. Inside, the signal was homogeneous, and a "flow void" signal from the portal vein and hepatic veins can be seen. (B) T2WI showed that the mass had the same signal intensity as normal liver tissue and vascular opacities can be seen inside. (C) Coronal scanning showed that the mass was demarcated from normal liver tissue by a low signal line. (D) Vertical scanning showed that the mass was connected to the right lobe by a stalk of tissue.

and a uniform density. Hepatic veins were connected to the inferior vena cava (Figure 2B). Delayed phase: The mass was demarcated from normal liver tissue by an enhanced line (Figure 2C). CT diagnosis: Completely separate ALL.

2.3. Case Three

A 9-year-old female was brought to the hospital due to coughing, expectoration, and a fever lasting 3 days. The clinical diagnosis was pulmonary infection. Plain films showed a lesion occupying the right lower lung field; its density was uniform and most of its margins were distinct except at the surface of the diaphragm. T2WI showed a quasi-circular mass in the right posterior lobe of the liver; its margins were distinct and its signal intensity was homogeneous and the same as that of the right lobe of the liver (Figure 3A). Coronal scanning showed a mass located at the rear of the right lobe with its base connected to the right lobe and a continuous vascular structure inside (Figure 3B). Sagittal scanning showed that the mass connected to the right lobe via a

wide base, and vessels heading to the right lobe were apparent (Figure 3C). MRI diagnosis: Sessile ALL.

3. Discussion

3.1. The mechanism of ALL

Meckel reported several cases of ALLs (3). An ALL is an anatomical abnormality that is rarely seen and is mostly the result of embryonic heteroplasia (4,5), though in rare instances an ALL may occur after trauma or surgery (6). As a type of congenital anatomical malformation, ALL occurs very rarely because it is associated with an autosomal recessive gene with a very low frequency. Anatomical research through necropsies of 172 rats confirmed this genetic theory (8). Currently, there are two hypotheses of the mechanism of an ALL: (i) the embryonic liver curls outwards and forms an accessory lobe during the embryonic stage of development (10) or (ii) an accessory lobe arises from intra-abdominal hypertension caused by the development of the tunica muscularis recti and the enlargement of the liver (11).

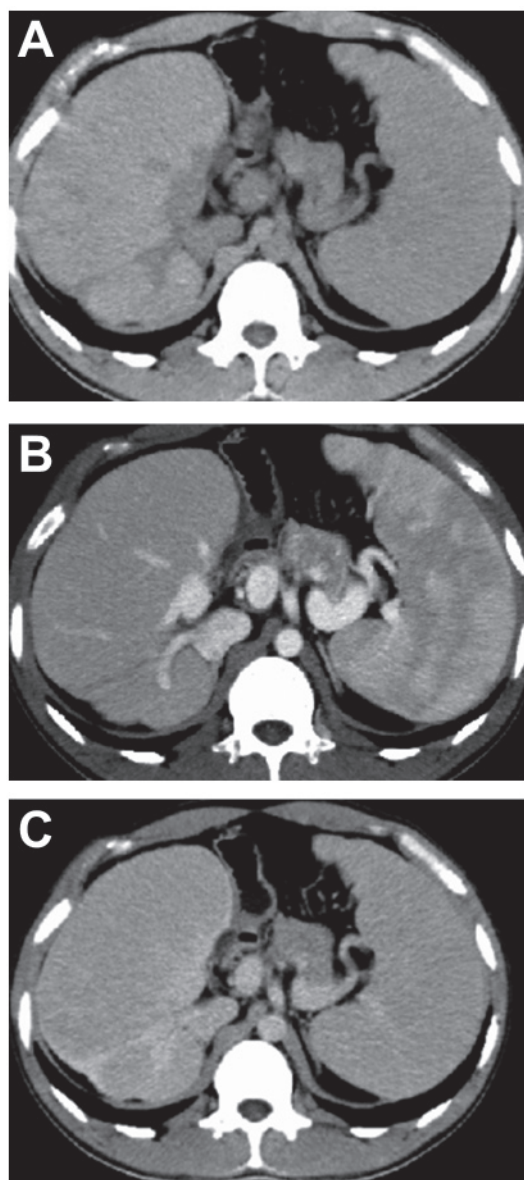


Figure 2. Case Two. (A) A CT scan showing an irregular mass at the back of the inferior vena cava and the liver; its density was uniform and the mass was clearly divided from normal liver tissue. (B) Enhanced scanning showed hepatic veins connected to the inferior vena cava. (C) Delayed phase: The mass had the same density as normal hepatic tissue and was demarcated from normal liver tissue by an enhanced line.

3.2. Classification of ALL

There is little literature about the classification of ALL. ALL can be classified into two types according to Stattaus (1): an accessory lobe joined to normal hepatic tissue or a completely separate accessory lobe. An ALL can also be classified as pedunculated or sessile. There are several types of ALL that are classified by volume and weight (4,6,12): (i) a bulky ALL (> 31 g) connected to the liver *via* a stalk of tissue or wide base in the subphrenic or perihepatic zone; (ii) a small ALL (11-30 g) connected to the liver *via* a wide base on the surface of the liver or around the right posterior lobe; (iii) a completely separate ALL with no connection to

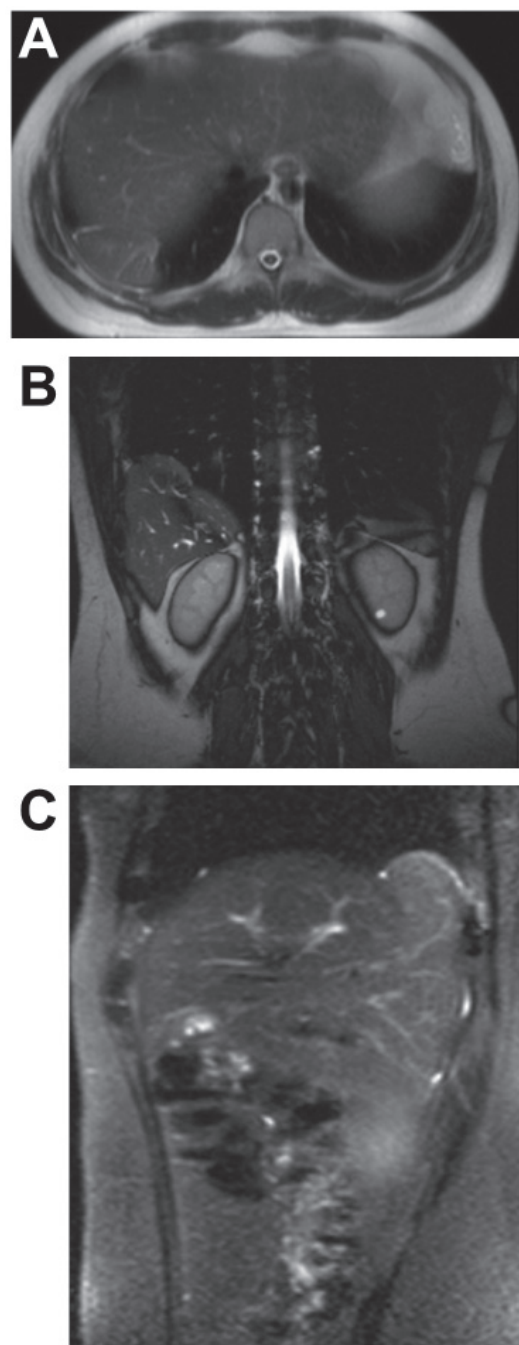


Figure 3. Case Three. (A) T2WI conventional scanning: A mass is located at the rear of the right lobe of the liver, its margins are distinct, its signal intensity is the same as the right lobe, and vascular opacity can be seen inside. (B, C) Enhanced scanning: Coronal scanning and sagittal scanning showed a mass located at the posterior-lateral costophrenic angle connected to the right lobe of the liver by a wide base. Vascular opacities are apparent inside the mass.

normal liver tissue that is most often seen in the thorax or pelvic cavity (4,13,14); or (iv) a pinpoint atopic ALL (< 10 g) that is most often located at the margins of the liver or even gallbladder wall. An abdominal ALL, and especially a right abdominal ALL, is reported relatively frequently. There are few reported cases of an ALL located in the thorax or pelvic cavity (5,15,16). In the 3 cases reported here, the ALL was connected to normal liver tissue: 1 case involved a pedunculated ALL while

2 involved a sessile ALL. Classified by volume and weight, 1 case involved a bulky ALL while 2 involved a small ALL. All of the accessory lobes were located at the posterior costophrenic angle and on the surface of the liver.

3.3. Clinical features

Most patients with an ALL have no symptoms and are seldom diagnosed in the early stages. Most ALLs are discovered unexpectedly during surgery or autopsy. The rate of ALL detection is increasing thanks to advances in imaging equipment and the greater prevalence of physical examinations (5,15,16). Patients with an ALL and no complications have no symptoms or physical signs but may occasionally present with acute stomachaches, recurring stomachaches (1), precordial pain, nausea, or vomiting (17). Though these problems are worse than the dyspnea caused by an ALL in the thorax (18), they are not specific indicators of an ALL. The clinical manifestations of an ALL depend on complications, such as torsion of an ALL, traumatic rupture, or infarction (6). Torsion of an ALL is most frequent and severe complication. Most patients with torsion of an ALL visit the hospital complaining of a severe stomachache due to hemadostenosis, vascular obstruction, ischemia, putrescence, or even rupture and bleeding (19-21). During the 7th and the 8th week of embryo development, which is when the muscular layer of the abdominal wall is formed, development of an ALL in the embryo may obstruct the closing of the umbilical ring (3,10), which is why most ALLs are associated with acromphalus. ALLs are also associated with congenital biliary atresia (22), congenital diaphragmatic defects, and angiocavernoma (8). Most reported cases of an ALL involve females ranging in age from newborns to 75 years. One of the current cases involved a male while the other two involved females. The male was age 20 while the females were age 9 and 59. One was diagnosed with an ALL based on a CT scan after a physical examination while the other two were diagnosed during a CT/MRI scan.

3.4. The diagnosis of ALL

ALL is rarely seen clinically and is difficult to diagnose before surgery (2). It is often misdiagnosed because most patients with an ALL have no symptoms (8). Many cases of an ALL were mis-diagnosed as an intraperitoneal tumor, pulmonary tumor, or diaphragm tumor (23-25). The position of an ALL varies in each individual. An ALL is typically detected and diagnosed *via* plain films, contrast enhancement, radioactive species, type-B ultrasound, CT, or MRI (5,26-28). Most previous cases of ALL were diagnosed by pathology after surgery (23,26,29), though a few were diagnosed

by imaging before surgery (4,27,28,30). Rapid advances in medical imaging equipment such as that used for ultrasound, CT, MRI, PET, and especially multi-slice spiral CT (MSCT) and MRI multiplane imaging provides more accurate information for diagnosis of an ALL, including its size, shape, classification, position, and blood supply. Thus, an increasing number of patients with ALL can be accurately diagnosed in the early stages or before surgery (5,31,32). A look at the CT and MRI findings from the 3 current cases indicates that: (i) according to CT/MRI scanning and enhanced scanning, the substantive part of the accessory lobe had the same density or signal as normal liver tissue; (ii) the ALL had distinct and smooth margins, with complete demarcation; (iii) the ALL was connected to normal liver tissue *via* a stalk of tissue or base; (iv) flowing-void vascular imaging was apparent during MRI scanning and venous imaging was apparent during enhanced CT/MRI scanning. An ALL connected to normal liver tissue can be accurately diagnosed based on these findings, though diagnosing a completely separate ALL is difficult since it cannot be readily differentiated from a mediastinal neoplasm or peripheral tumor.

3.5. Differential diagnosis

An ALL connected to normal liver tissue can be readily diagnosed based on CT/MRI characteristics though diagnosis of a completely separate ALL is difficult. In order to make an accurate diagnosis, factors such as size, shape, position, whether complications are present or not, and the type of complication should be considered. In terms of position, (i) an ALL in the thorax should be differentiated from a tumor of the pleura, lungs, chest wall, or diaphragm (1,4,24,26) while (ii) an ALL in the pelvic cavity should be differentiated from a benign or malignant tumor of the pelvic organs (33) and (iii) an ALL on the surface of the liver or abdominal organs should be differentiated from pathological changes in the liver, gall bladder, pancreas, spleen, or adrenal glands (13,22). Most patients with an ALL have no clinical manifestations and the ALL may be large enough to jostle surrounding organs. This is completely distinct from an invading malignant tumor that destroys surrounding tissue and metastasizes to distant organs. Differentiating a completely separate ALL from a benign tumor is difficult without a pathological examination after surgery.

Patients with a pedunculated ALL may suffer acute stomachaches, abdominal distension, nausea, vomiting, or shock while they have complications of reversion, hemorrhage, or infarction (5,6,25,28,34-38). Since such an ALL can easily be mistaken for an acute abdomen or abdominal tumor, CT or MRI imaging should facilitate differentiation.

3.6. Complications

Patients with an ALL may have overt symptoms or their lives may be in danger if they have complications (39). Reported complications include reversion, infarction, hemorrhage, fracture, hemangioma, biliary atresia, gallbladder torsion, hepatic dysfunction, diaphragm defects, and acromphalus (40). Whether complications are present or not and the type of complication relate to the patient's age and the type, size, and position of the ALL. Most infants with an ALL also have congenital acromphalus, congenital biliary atresia, or gallbladder torsion (22,41). A pedunculated ALL carries a higher incidence of reversion than the other types of ALLs. Severe congestion and blood stasis result from an insufficient blood supply, vastly increasing the incidence of vascular ruptures (10,21). In cases of an ALL, one complication is often joined by others, just as reversion of an ALL occurs concurrently with infarction and rupture (17,20). Complications of an ALL can be classified as acute or chronic complications; the former are caused by strenuous exercise or trauma (6,28,38) while the latter, such as persistent hepatic dysfunction (40), do not appear in the early stages but do present as the ALL develops.

3.7. Treatment and prognosis

There is no need to treat patients with an ALL who have no symptoms or complications (13). A liver transplant or resection of the ALL should be performed for patients with serious complication at birth such as acromphalus, biliary atresia, or gallbladder torsion (42,43). Resection of the ALL should be performed in adults with serious complications. Patients are reported to have a satisfactory prognosis. There is no need to treat patients with a sessile ALL connected to normal liver tissue or completely separate ALL if they have no symptoms or complications. If a patient is diagnosed with a pedunculated ALL, surgery should be performed as soon as possible in order to avoid unexpected complications.

References

- Stattaus J, Kühl H, Forsting M. Diagnosis of an accessory liver lobe established by magnetic resonance imaging-guided core biopsy. *Z Gastroenterol*. 2008; 46:351-354. (in German)
- Pérez-Martínez A, Conde-Cortés J, Martínez-Bermejo MA, Bento-Bravo L. Torsion of a pedunculated accessory hepatic lobe: Differential diagnosis of projectile vomiting in a neonate. *J Perinat Med*. 2006; 34:248-249.
- Johnstone G. Accessory lobe of liver presenting through a congenital deficiency of anterior abdominal wall. *Arch Dis Child*. 1965; 40:541-544.
- Tancredi A, Cuttitta A, de Martino DG, Scaramuzzi R. Ectopic hepatic tissue misdiagnosed as a tumor of lung. *Updates Surg*. 2010; 62:121-123.
- Jambhekar K, Pandey T, Kaushik C, Shah HR. Intermittent torsion of accessory hepatic lobe: An unusual cause of recurrent right upper quadrant pain. *Indian J Radiol Imaging*. 2010; 20:135-137.
- Garba ES, Ameh EA. Isolated rupture of an accessory liver from blunt abdominal trauma in childhood. *Pediatr Surg Int*. 2002; 18:62-63.
- Wright JR Jr, Sharma HM, Yates AJ, Thompson BM, Thibert P. Supradiaphragmatic accessory lobe of the liver in BB Wistar rats. *Teratology*. 1983; 27:117-120.
- Pujari BD, Deodhare SG. Symptomatic accessory lobe of liver with a review of the literature. *Postgrad Med J*. 1976; 52:234-236.
- Llorente J, Dardik H. Symptomatic accessory lobe of the liver associated with absence of the left lobe. *Arch Surg*. 1971; 102:221-223.
- Ito F, Ando H, Watanabe Y, Seo T, Murahashi O, Harada T, Kaneko K, Ishiguro Y. An accessory lobe of the liver disturbing closure of the umbilical ring. *Pediatr Surg Int*. 1999; 15:394-396.
- Nora E, Carr CE. Umbilical accessory liver. *Am J Obstet Gynecol*. 1946; 52:330-335.
- Mehta V, Arora J, Manik P, Suri RK, Rath G. Clinico-anatomical aspects of accessory fissures obscuring the normal hepatic morphology. *Clin Ter*. 2010; 161:259-260.
- Olinde HD, Boggs HW Jr. Infarction of an accessory lobe of the liver. *AMA Arch Surg*. 1958; 77:650-651.
- Rodriguez-Perez D. Accessory intrapleural ectopic liver lobe. *Bol Asoc Med PR*. 1955; 47:353-356.
- Han S, Soyul L. Accessory liver lobe in the left thoracic cavity. *Ann Thorac Surg*. 2009; 87:1933-1934.
- Sangüesa C, Esteban MJ, Gomez J, Cotina H. Liver accessory lobe torsion in the infant. *Pediatr Radiol*. 1995; 25:153-154.
- Negru D, Tudorache C, Marinescu M, Grigora M, Crumpei F, Georgescu S. Torsion and infarction of an accessory liver lobe. *Rev Med Chir Soc Med Nat Iasi*. 2007; 111:442-445. (in Romanian)
- Luoma R, Raboei E. Supradiaphragmatic accessory liver: A rare cause of respiratory distress in a neonate. *J Pediatr Surg*. 2003; 38:1413-1414.
- Ozturk E, Baskim CC, Kantarci M, Kizilkaya E. Giant accessory liver lobe. *J Gastroenterol Hepatol*. 2006; 21:335-336.
- Carrabetta S, Piombo A, Podestà R, Auriati L. Torsion and infarction of accessory liver lobe in young man. *Surgery*. 2009; 145:448-449.
- Machado EA, Lozzio BB. Accessory lobe of the liver in Gunn-derived rats. *Teratology*. 1972; 5:361-365.
- Faraj W, Dar F, Marangoni G, Alvarez FE, Howlader M, Mukherji D, Heaton N, Rela M. Liver transplantation for syndromic biliary atresia with a pedunculated accessory hepatic lobe. *Pediatr Transplant*. 2010; 14:E1-E3.
- Wang Y, Junlin L, Zhang WG, Chen JH, He Y, Chen JM. Accessory lobe of right liver mimicking a pulmonary tumor in an adult male. *Ann Thorac Surg*. 2010; 89:e9-e10.
- Vykouril L. An uncommon cause of acute abdomen – hemorrhage into an accessory hepatic lobe. *Rozhl Chir*. 1989; 68:253-257. (in Czech)
- Kuroiwa T, Hirata H, Iwashita A, Yasumori K, Mogami H, Teraoka H. Accessory hepatic lobe simulating a left hemidiaphragmatic tumor: A case report. *Nihon Igaku Hoshasen Gakkai Zasshi*. 1984; 44:1033-1037.
- Kostov DV, Kobakov GL. Accessory hepatic lobe. *Surg*

- Radiol Anat. 2011; 33:819-822.
27. Koplewitz BZ, Manson DE, Ein SH. Posttraumatic torsion of accessory lobe of the liver and the gallbladder. *Pediatr Radiol*. 1999; 29:799-802.
 28. Watson JR, Lee RE. Accessory lobe of the liver with infarction. *Arch Surg*. 1964; 88:490-493.
 29. Hundal RS, Ali J, Korsten MA, Khan AM. Torsion and infarction of an accessory liver lobe. *Z Gastroenterol*. 2006; 44:1223-1226.
 30. Bedda S, Bataille N, Montariol T, Zareski E. Accessory liver lobe torsion mimicking a pancreatic tumor. *Ann Chir*. 2003; 128:53-54. (in French)
 31. Koumanidou C, Nasi E, Koutrouveli E, Theophanopoulou M, Hilari S, Kakavakis K, Batakis N. Torsion of an accessory hepatic lobe in a child: Ultrasound, computed tomographic, and magnetic resonance imaging findings. *Pediatr Surg Int*. 1998; 13:526-527.
 32. Go RT, Van Kirk OC, Schapiro RL, Christie JH. Accessory left hepatic lobe – diagnostic contributions by various imaging techniques. *J Comput Tomogr*. 1978; 2:155-158.
 33. Levi MM, Creque LC, Cinque S. Accessory lobe of liver presenting symptoms of pelvic tumor. *N Y State J Med*. 1969; 69:1334-1336.
 34. Massaro M, Valencia MP, Guzman M, Mejia J. Accessory hepatic lobe mimicking an intra-abdominal tumor. *J Comput Assist Tomogr*. 2007; 31:572-573.
 35. Umehara M, Sugai M, Kudo D, Hakamada K, Sasaki M, Munakata H. Torsion of an accessory lobe of the liver in a child: Report of a case. *Surg Today*. 2009; 39:80-82.
 36. Betge L. The torsion of an accessory liver lobe as the rare cause of acute abdomen. *Dtsch Med Wochenschr*. 1995; 120:1318-1320.
 37. Tomooka Y, Torisu M, Fujimura T, Sakaguchi N, Taira A. Symptomatic accessory lobe of the liver associated with hyperthyroidism. *J Pediatr Surg*. 1988; 23:1055-1056.
 38. Peter H, Strohm WD. Contortion of an accessory lobe of the liver causing acute abdominal distress (author's transl). *Leber Magen Darm*. 1980; 10:203-206.
 39. Ladurner R, Brandacher G, Mark W, Iannetti C, Lottersberger C, Steurer W, Königsrainer A, Margreiter R. Complete hepatic ischemia due to torsion of a large accessory liver lobe: First case to require transplantation. *Transpl Int*. 2005; 18:467-469.
 40. Fogh J, Tromholt N, Jørgensen F. Persistent impairment of liver function caused by a pendulated accessory liver lobe. *Eur J Nucl Med*. 1989; 15:326-327.
 41. Festen C, Severijnen RS, vd Staak FH. Gallbladder embedded in an accessory liver lobe in umbilical cord hernia. *J Pediatr Surg*. 1988; 23:978-979.
 42. Tan KL, Tan AY. Accessory lobe of the liver in an exomphalos with biliary atresia. *J Singapore Paediatr Soc*. 1971; 13:97-100.
 43. Pereira RM, Simões e Silva AC, Leite VH, Lanna JC, Guimarães JT. Successful management of concomitant omphalocele, accessory hepatic lobe, and biliary atresia in a 44-day-old boy. *J Pediatr Surg*. 2005; 40:e21-e24.

(Received November 29, 2011; March 28, 2012;
Accepted April 23, 2012)