

Tetraploid acute promyelocytic leukemia with double translocation t (15,17) PML/RARA: the first case report in Croatia and Europe

Vlatka Periša^{1,2,*}, Dorian Laslo¹, Ivana Franić-Šimić³, Jasminka Sinčić-Petričević²

¹ Faculty of Medicine Osijek, University Josip Juraj Strossmayer of Osijek, Osijek, Croatia;

² University Hospital Centre Osijek, Clinic of Internal Medicine, Department of Hematology, Osijek, Croatia;

³ Clinical Hospital Centre Zagreb, Clinical department for laboratory diagnostics, Zagreb, Croatia.

SUMMARY Acute promyelocytic leukemia (APL) is characterized by the translocation t (15;17)(q22;q21) cytogenetic abnormality in the majority of cases. In most of the cases the cells of APL have normal, diploid karyotype. There are very few cases presented with very rare tetraploid karyotype with double translocation t(15;17)(q22;q12). We report the first case of tetraploid APL with double translocation t(15, 17) in Europe. A 66-year old male patient presented with dyspnea and unexplained dental bleeding. Blood work showed a white blood cell count of $1 \times 10^9/L$, hemoglobin was 124 g/L, platelet count was $61 \times 10^9/L$ and fibrinogen level was low (1.4 g/L). Cytogenetics showed a tetraploid karyotype. Fluorescence in situ hybridization analysis proved existence of clonal cells with translocation t (15,17) in 15% of metaphase nuclei and tetraploid subclonal cells with the same translocation in 70% of metaphase nuclei. Findings were consistent with APL, tetraploid variant and the patient started all-trans retinoic acid (ATRA) treatment. The patient achieved complete remission in 2 months and completed three consolidation therapy cycles with ATRA, idarubicin or mitraxontrate. Currently, the patient is undergoing maintenance therapy with ATRA, 6-mercaptopurine and weekly methotrexate.

Keywords acute promyelocytic leukemia, all trans-retinoic acid (ATRA), PML-RARA, tetraploid

1. Introduction

Acute promyelocytic leukemia (APL) is a type of acute myeloid leukemia (AML), classified according to the French-American-British (FAB) classification as AML-M3 and accounts for about 10-15% of all AMLs. APL is characterized by a balanced reciprocal translocation (t) between chromosomes 15 and 17 resulting in the fusion of the retinoic acid receptor alpha (RARA) and promyelocytic leukemia (PML) genes in the majority of cases. In most of the cases the cells of APL have normal, diploid karyotype (1,2). There are very few cases presented with very rare tetraploid karyotype with double translocation t (15;17)(q22;q12). Tetraploidy has only been reported in 16 cases of APL in the literature, with cases reported in the Far East countries, Australia, United States of America, Malaysia and Greece (3-5).

We searched PubMed using key words "acute promyelocytic leukemia" and "tetraploid" and found 20 results. None of those results was related to Croatia, thus, to our knowledge, our case is the first reported tetraploid APL with double t (15;17)/PML-RARA in

an adult from Croatia. Furthermore, until now only one APL with tetraploidy case report has been published in Europe (5) but in that case report t (15;17)(q22;q12) has not been proven. Accordingly our case report is the first case of tetraploid APL with double t (15;17)(q22;q21).

2. Case Report

We present a case of a 66-year old male patient who presented with dyspnea, and dental bleeding. Blood work showed a white blood count of $1 \times 10^9/L$ with 39% neutrophils, 49% lymphocytes and 5% monocytes. The hemoglobin was 124 g/L and the platelet count was $61 \times 10^9/L$.

The prothrombin and activated partial thromboplastin time were normal but fibrinogen level was low (1.4 g/L). The bone marrow showed numerous large promyelocytes (54%) that contained irregular bilobed nuclei, abundant cytoplasm with granularity and few Auer Rods. Flow cytometry showed a population of large immature cells phenotypically positive for cluster of differentiation (CD)13, CD33, myeloperoxidase (MPO), CD117, CD56, CD64, CD2 and negative

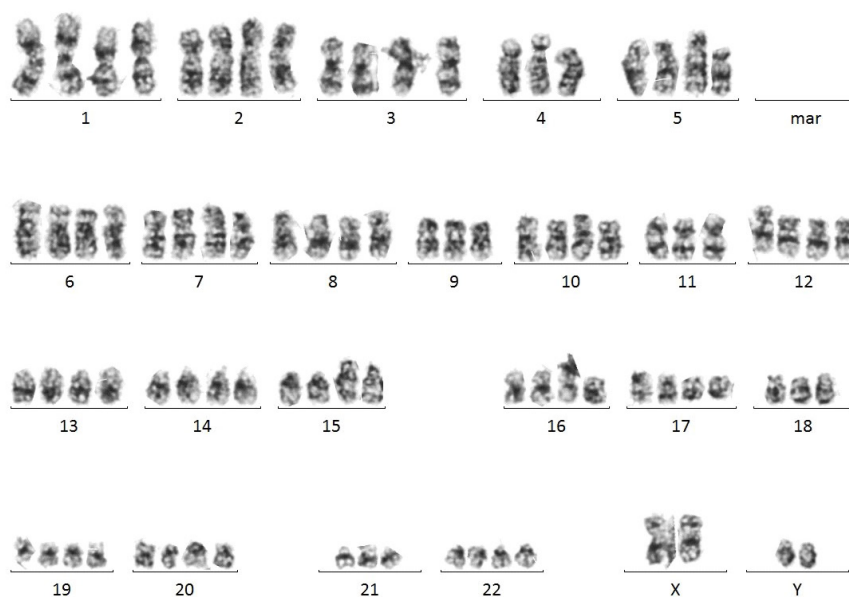

Figure 1. Karyogram of tetraploid subclone of acute promyelocytic leukemia cells.

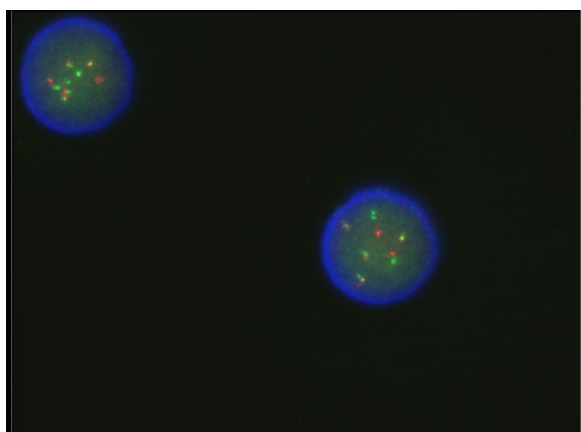


Figure 2. Fluorescence in situ hybridization analysis of tetraploid translocation $t(15,17)(q21,q22)$ with PML/RARA probe.

for Human Leukocyte Antigen – DR isotype (HLA-DR) and CD11c which referred to promyelocytes. Cytogenetics showed a tetraploid karyotype as follows: $46,XY,t(15;17)(q22;q21)/92,XXYY,t(15;17)(q22;q21) \times 2$ (Figure 1). Fluorescence in situ hybridization (FISH) analysis proved existence of clonal cells with translocation $t(15,17)$ in 15% of metaphase nuclei and tetraploid subclonal cells with the same translocation $t(15,17)$ in 70% of metaphase nuclei (Figure 2). PML/RARA copies were identified by a reverse transcriptase-polymerase chain reaction (RT-PCR).

Findings were consistent with APL, tetraploid variant. Induction therapy with all trans-retinoic acid (ATRA) and idarubicin were completed with no complications. Post induction bone marrow cytogenetics revealed a normal male karyotype and FISH and PCR studies showed no PML/RARA fusion products, consistent with APL in molecular remission.

The patient achieved a complete remission in 2 months and completed three consolidation therapy cycles with ATRA, idarubicin or mitraxontrate with 28 months of follow up. Repeat bone marrow examination and molecular analysis after completion of consolidation treatment showed the patient remained in morphological and molecular remission. The latest molecular analysis which was done 50 weeks after consolidation therapy revealed undetectable PML-RARA fusion copies. Currently, the patient is undergoing maintenance therapy with ATRA, 6-mercaptopurine and weekly methotrexate.

3. Discussion

In most cases APL is characterized with giant and bizarre blast cells translocation $t(15,17)(q21,q22)$ and synthesis of fusion transcriptional product PML/RARA. Initial treatment of APL includes application of ATRA with or without additional chemotherapeutics or idarubicine. Tetraploidy with double translocation $t(15,17)$ is an extremely rare finding. To our knowledge this is the 17th published case of tetraploid APL (3,4).

Clinical presentation of APL (with or without tetraploidy) is the same. It is characterized by sudden start of heavy hemorrhage associated with high risk of disseminated intravascular coagulopathy development (6). It seems that tetraploidy does not influence the initial treatment response in patients with tetraploidy with double translocation (7). Counting this case report 14 out of 17 patients had complete cytogenetic and hematological remission as a result of initial treatment using ATRA with or without additional chemotherapeutics. It seems that there is no positive correlation between age and long term outcome.

Table 1. The most important clinical findings of previously published tetraploid APL case reports*

No.	Country	Authors	Age/Sex	Immunophenotype	Cytogenetics
1	Japan	Kaito <i>et al.</i>	56/M	CD2+, CD13+, CD33+, CD34+, CD56+, HLA-DR-	92,XXYY,t(15;17)(q22;q21) × 2
2	South Korea	Oh <i>et al.</i>	50/F	CD2+, CD13+, CD33+, CD34+, CD56-, HLA-DR-	92,XXXX,t(15;17)(q22;q21) × 2
3	Japan	Morita <i>et al.</i>	50/M	CD2+, CD13+, CD33+, CD34+, HLA-DR+	45,XY,add(1)(p36),9,der(15)t(15;17),17,add(20)(q13),21,mar1,mar2[2]/46,idem,mar3[6]/45,idem,del(11)(p11),add(13)(p11),18,21,mar1,mar2[2]/86,XX,Y,add(6)(p21) × 2,8,9,11,12,der(15)t(15;17)(q22;q11-q21) × 2,16,17,17,18,19,mar4,mar5[2]/46,XY[5]
4	Australia	Mohamed <i>et al.</i>	32/M	CD13+, CD33+, CD34+, CD117+, HLA-DR-	92,XXXX,t(15;17)(q22;q21) × 2
5	United States	Ravella <i>et al.</i>	48/M	CD2-, CD13+, CD33+, CD34+, CD56-, CD117-, HLA-DR-	92,XXYY,t(15;17)(q22;q21)X2[4]/92,XXYY,add(5)(q22),t(15;17)(q22;q21)X2[3]/46,XY[13]
6	China	Pan <i>et al.</i>	21/M	CD2+, CD13+, CD33+, CD117+	46,XY,t(15;17)[18]/92,XXYY,t(15;17) × 2[6]/46,XY
7	China	Pan <i>et al.</i>	26/M	CD2+, CD13+, CD33+	92,XXYY,t(15;17) × 2
8	China	Pan <i>et al.</i>	68/M	CD2+, CD13+, CD33+, MPO+	92,XXYY,t(15;17) × 2[5]/46,XY
9	China	Pan <i>et al.</i>	40/M	CD13+, CD33+	92,XXYY,t(15;17) × 2
10	China	Pan <i>et al.</i>	38/M	CD33+	92,XXYY,t(15;17) × 2[18]/46,XY
11	China	Au <i>et al.</i>	24/M	CD2+, CD13+, CD33+, MPO+	73-89,XXY,-Y[18],-3[10],-5[9],-11[9],-14[10],-15[9],t(15;17)[10],t(15;17)[4],der(15)t(15;17)[4],-17[8],-18[7],-19[9],-20[18],+mar2 × 2[10],+mar3[7]/cp10/46,XY
12	Japan	Kojima <i>et al.</i>	53/M	Not available	92,XXYY,del(2)(q?),t(15;17)(q22;q12) × 2,-16,-16,+2mar[4/6]
13	Japan	Kuyama <i>et al.</i>	56/M	CD2-, CD13+, CD33+, CD34+, CD56-, HLA-DR	92,XXYY
14	Greece	Matsouka <i>et al.</i> [§]	49/M	CD13+, CD33+, CD34+, CD38+, CD56+, HLA-DR-	91,XXYY,-9,(15;17)(q24;q21.1) × 2
15	United States	Dalia <i>et al.</i>	51/M	CD7-, CD13+, CD33+, CD34+, CD56+, CD117+, MPO+, HLA-DR-	89-92,XXYY,t(15;17)(q22;q21) × 2[7]/46,XY[5]
16	Malaysia	Tay Za <i>et al.</i>	57/M	CD13+, CD33+, CD117+, cMPO+, CD34+(heterogenous), CD64+, CD56+, CD2+, HLA-DR-, CD11b-, CD15-, CD14-, CD41, CD61-, CD71-, glycothorin-	46,XY,t(15;17)(q22;q21)92,XXYY,t(15;17)(q22;q21) × 2
17	Croatia	Our case	66/M	CD13+, CD33+, MPO+, CD117+, CD56+, CD64+, CD2+ HLA-DR-, CD11c-	

*Data from published studies (Ref. 3-5). [§]Tetraploidy without double t (15;17)

Three patients at ages under 60 years died despite ATRA treatment, and on the other hand three patients above the ages of 50 and one patient at the age of 68 achieved complete remission (4). Influence of additional chromosome anomalies (ACA) in long-term survival of the patients with non-tetraploid APL was analyzed and it was estimated that trisomy 8 is the most frequent ACA, but it was concluded that ACAs have no influence on treatment response or survival (8).

Counting this case report, until now only 17 case reports were published and 11 of them were patients from the Far East (Japan, China, Korea). Table 1 summarizes the 17 cases of tetraploidy APL (3-5). Since there was no difference in therapy response or long-term survival between patients from Far East and other countries, that difference in patients distribution could be caused by publicational bias (4,5) especially if we take into account that only two case reports were published from Western hemisphere countries (4,9), and counting this case report, only two from Europe (5). What could be significant is that male sex could have greater risk for tetraploid APL development, since only 1 out of 17 patients was a woman at the age of 50 (6). Complete remission was achieved in 14 out of 17 cases, but long-term survival of the patients with tetraploid APL compared to those with non-tetraploid APL seems to be lower, but for now the number of tetraploid APL patients is too low for any firm conclusions about long-term survival.

4. Conclusion

We report the first case of tetraploid APL with double translocation t(15,17) in Europe. Based on the previous reports, APL with tetraploid karyotype appears to have a similar clinical outcome to diploid APL. Nevertheless, it is difficult to draw a firm conclusion in regards to the long-term prognosis of APL patients with a tetraploid karyotype due to the very small number of such cases reported. We encourage others to report cases of tetraploidy APL in order to understand this rare cytogenetic subgroup better.

Funding: None.

Conflict of Interest: The authors have no conflicts of interest to disclose.

References

1. Jimenez JJ, Chale RS, Abad AC, Schally AV. Acute promyelocytic leukemia (APL): a review of the literature. *Oncotarget*. 2020; 11:992-1003.
2. Cicconi C, Lo-Coco F. Current management of newly diagnosed acute promyelocytic leukemia. *Ann Oncol*. 2016; 27:1474-1481.
3. Tay Za K, Jackson N, Chin EFM. Tetraploid/near-tetraploid acute promyelocytic leukaemia with double (15;17) translocation. *Malaysian J Pathol*. 2020; 42:127-130.
4. Dalia SM, Horna P, Zhang L. Tetraploidy acute promyelocytic leukemia with double t(15;17)/PML-RARA, a case report with review of literature. *Int J Clin Exp Pathol*. 2014; 7:5363-5368.
5. Matsouka P, Sambani C, Giannakoulas N, Symeonidis A, Zoumbos N. Polyploidy in acute promyelocytic leukemia without the 15:17 translocation. *Haematologica*. 2001; 86:1312-1313.
6. Oh SH, Park TS, Kim HH, Chang CL, Lee EY, Son HC, Chung JS, Cho GJ. Tetraploid acute promyelocytic leukemia with double t(15;17) and PML/RARA rearrangements detected by fluorescence in situ hybridization analysis. *Cancer Genet Cytogenet*. 2003; 145:49-53.
7. Pan J, Xue Y, Qiu H, Wu Y, Wang Y, Zhang J, Shen J. Tetraploid clone characterized by two t(15;17) in five cases of acute promyelocytic leukemia. *Cancer Genet Cytogenet*. 2009; 188:57-59.
8. Ono T, Takeshita A, Iwanaga M, Asou N, Naoe T, Ohno R; Japan Adult Leukemia Study Group. Impact of additional chromosomal abnormalities in patients with acute promyelocytic leukemia: 10-year results of the Japan Adult Leukemia Study Group APL97 study. *Haematologica*. 2011; 96:174-176.
9. Ravella PM, Liu D, Kojima K, Weisberger J, Miura O, Kuyama J, Au W, Seiter K. Acute promyelocytic leukemia with tetraploid karyotype: first report in the Western hemisphere and update of previous reports. *Leuk Res*. 2011; 35:93-95.

Received November 15, 2020; Revised January 20, 2021; Accepted January 27, 2021.

**Address correspondence to:*

Vlatka Periša, Faculty of Medicine Osijek, University Josip Juraj Strossmayer of Osijek, Osijek, Croatia and University Hospital Centre Osijek, Clinic of Internal Medicine, Department of Hematology, Osijek, Croatia.
E-mail: vlatkaperisa@gmail.com

Released online in J-STAGE as advance publication February 5, 2021.