

Intraventricular pilocytic astrocytoma in an adult patient

Joshua Hendrix, Zhenggang Xiong*

Department of Pathology and Laboratory Medicine, Robert Wood Johnson Medical School, Rutgers University, NJ, USA.

SUMMARY Pilocytic astrocytomas are tumors of the central nervous system mostly during the first two decades of life. Although they are mostly common in the midline structures of children, pilocytic astrocytoma within the ventricular system of an adult is extremely rare. We report a case of a 38-year old woman with obstructive hydrocephalus secondary to a brain tumor within the third ventricle. On histological examination, the tumor exhibited biphasic growth pattern comprising compacted cellular areas with Rosenthal fibers and loose textured microcystic areas with eosinophilic granular bodies. Mitosis or necrosis was not present. Immunohistochemical studies demonstrated glial fibrillary acid protein (GFAP), Olig2, and ATRX positivity as well as NeuN and EMA negativity. Ki67 labeling index was less than 1%. Molecular studies revealed that there are no isocitrate dehydrogenase (*IDH*) gene mutation and *H3F3A* mutation. This clinical presentation along with the histologic and molecular findings is consistent with a pilocytic astrocytoma arising in the third ventricle of this adult brain, which indicates that pilocytic astrocytoma can present as an intraventricular tumor in an adult patient and should be routinely included in the differential diagnosis of intraventricular brain neoplasm.

Keywords pilocytic astrocytoma, ventricle, central nervous system, adult

1. Introduction

Pilocytic astrocytomas are tumors of the central nervous system (CNS) most commonly occurring during the first two decades of life with a peak incidence between 8 and 13 years of age. Although these tumors are typically located in the midline structures of CNS, like posterior fossa, cerebellum, thalamus, hypothalamus, etc., they rarely arise within a cerebral ventricle of an adult patient (1). In contrast to other low grade astrocytomas, pilocytic astrocytomas are associated with absence of isocitrate dehydrogenase (*IDH*) gene mutation. In some of cases, but not all cases, *KIAA 1549/BRAF* gene fusion is present. Literature review indicates that only a single prior case of intraventricular pilocytic astrocytoma has been histologically and molecularly identified in an adult patient (2). We report another histologically and molecularly confirmed case here to further support that pilocytic astrocytoma can occur intraventricularly in an adult patient.

2. Case Report

2.1. Clinical history

The patient was a 38-year-old woman with no significant medical history who reported a new brain mass and

obstructive hydrocephalus recently diagnosed in another hospital. She presented to our institution for further evaluation and treatment. She described five months of intermittent diplopia, tremors, and clumsiness. She was previously treated with levetiracetam and acetazolamide. At our institution, computed tomography (CT) confirmed moderate hydrocephalus with dilation of the lateral and third ventricles, without dilation of the fourth ventricle, as well as transependymal resorption of CSF indicating acute hydrocephalus. Magnetic resonance imaging (MRI) revealed a 12 mm rounded mass along the floor of the third ventricle with mild to moderate heterogeneous contrast-enhancement, obstructing the cerebral aqueduct (Figure 1). Subsequently, she underwent endoscopic ventriculostomy, in which a third ventricular tumor was identified and excised. The resulting specimen was sent to our neuropathology laboratory for evaluation.

2.2. Pathology

The surgical specimen comprised multiple small fragments of soft, pink-tan tissue. Cytological preparation for intra-operative consultation exhibited bipolar piloid cells with long, hair-like processes and elongated, moderately pleomorphic nuclei as well as smaller cells with short, cobweb-like processes

and round to oval nuclei. Rosenthal fibers and eosinophilic granular bodies were present. Mitosis was not identified. Histological examination of the paraffin-embedded tissue revealed a biphasic growth pattern composed of compacted cellular areas with Rosenthal fibers and loose textured microcystic areas with eosinophilic granular bodies. Mitosis, vascular endothelial hyperplasia or necrosis was not observed (Figure 2). Immunohistochemical studies demonstrated that the neoplastic cells expressed glial fibrillary acid protein (GFAP), Olig2, and ATRX, while IDH1 R132H, NeuN, and epithelial membrane antigen (EMA) were not present in the neoplastic cells. Ki67 labeling index was less than 1% (Figure 3). Next-generation sequencing study showed that there were no *IDH* mutation, *BRAF* alterations including *KIAA1549/BRAF* fusion, *H3F3A* mutation, and any other reported glioma-related genomic abnormalities (data not shown).

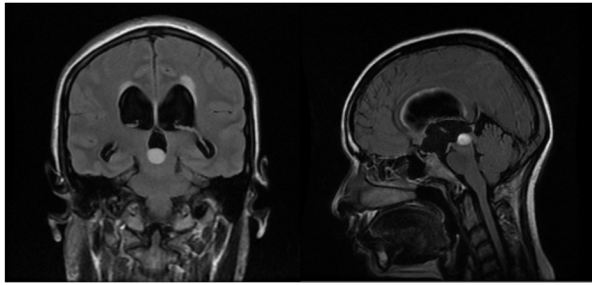


Figure 1. Magnetic Resonance Imaging, T2-weighted, showed a mild to moderate heterogeneous contrast-enhanced mass in the third ventricle.

3. Discussion

An intraventricular tumor is far more likely to arise from choroid plexus, ependyma, and subependymal tissue. Other less common intraventricular tumors include meningioma, lymphoma, and metastasis. Third ventricle tumors are rare and only comprise 0.6-0.9% of all brain tumors among all age groups (3,4). Within the category of third ventricle tumors, the most common includes colloid cysts, choroid plexus papillomas, and ependymomas. Occasionally, a pineal tumor can be located within the third ventricle. Although intraventricular pilocytic astrocytomas have been reported radiologically with or without limited histological examination (5,6), only one histologically and molecularly confirmed pilocytic astrocytoma within the lateral ventricle has been recently documented in the literature (2). In our case, neuroimaging demonstrated an obvious obstructing third ventricle mass which histologically exhibited classic pilocytic astrocytoma features, including biphasic growth pattern comprising compacted cellular areas and loose textured microcystic areas with Rosenthal fibers and eosinophilic granular bodies. Immunohistochemical studies demonstrated that the tumor cells are positive for glial fibrillary acid protein (GFAP), ATRX, and Olig2 with Ki67 labeling index of less than 1%, indicating astrocytic nature of low-grade glial neoplasm. Molecular studies revealed that there is no *IDH* gene mutation. The above supports the diagnosis of pilocytic astrocytoma. This case further supports that pilocytic astrocytoma can occur in the cerebral ventricular system including the third ventricle and

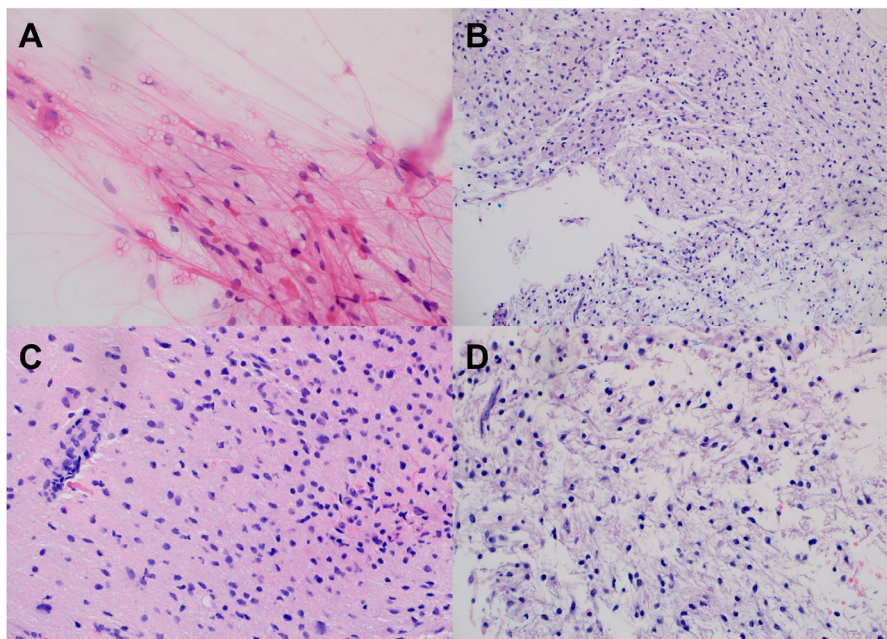


Figure 2. Histological examination observed two cell populations, bipolar piloid cells with long, hair-like processes and smaller cells with short, cobweb-like processes as well as a biphasic growth pattern composed of compacted cellular areas with Rosenthal fibers and loose textured microcystic areas with eosinophilic granular bodies. (A), smear preparation, H&E, 400 \times ; (B), tissue section, H&E, 200 \times ; (C) and (D) tissue section, H&E, 400 \times .

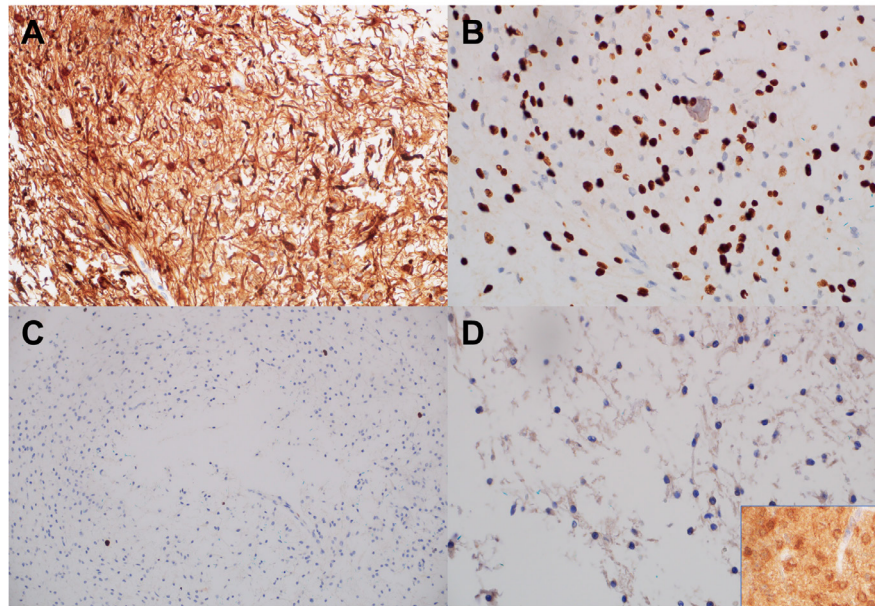


Figure 3. Immunohistochemical studies demonstrated that the neoplastic cells expressed GFAP and Olig2 with low Ki67 labeling index, but not IDH1 R132H mutant protein. (A), GFAP immunostaining, 400x; (B), Olig2 immunostaining, 400x; (C), Ki67 immunostaining, 200x; (D), IDH1 R132H immunostaining, 400x, insert: positive control.

should be in the differential diagnosis of intraventricular tumors.

Pilocytic astrocytoma accounts for 1.3% of all central nervous system tumors. It is the most common glioma in the pediatric population during the first two decades of life with median age of 12 years old, which declines dramatically from 14 years old to 15-19 years old. Approximately one third of gliomas in 0-14 years old patients are pilocytic astrocytoma (1,7). In adults, pilocytic astrocytoma is much less common. It usually occurs a decade earlier than diffuse astrocytoma and is rarely present in patients older than 50 years. It is worth noting that in contrast to another previously reported intraventricular pilocytic astrocytoma (2), this case does not harbor *KIAA 1549/BRAF* gene fusion. However, *KIAA 1549/BRAF* gene fusion is known to present much less frequently in adult patients with pilocytic astrocytoma, which suggests that the pathogenesis of intraventricular pilocytic astrocytoma may not necessarily be different from other extraventricular pilocytic astrocytomas (8).

Funding: None.

Conflict of Interest: The authors have no conflict of interest to disclose.

References

1. Louis DN, Ohgaki H, Wiestler OD, Cavenee WK, Ellison DW, Figarella-Branger D, Perry A. WHO Classification of Tumours of the Central Nervous System (4th edition) - Lyons: IARC Publications. 2016.
2. Ahn JS, Harrison W, Hughes E, McLendon RE. Intraventricular pilocytic astrocytoma with *KIAA1549/*

BRAF fusion arising in a 44-year old. *J Neuropathol Exp Neurol.* 2019; 78:187-190.

3. Ahmed SI, Javed G, Laghari AA, Bareeqa SB, Aziz K, Khan M, Samar SS, Humera RA, Khan AR, Farooqui MO, Shahbaz A. Third Ventricular Tumors: A Comprehensive Literature Review. *Cureus.* 2018; 10:e3417.
4. Glastonbury CM, Osborn AG, Salzman KL. Masses and malformations of the third ventricle: Normal anatomic relationships and differential diagnoses. *Radiographics.* 2011; 31: 1889-1905.
5. Xia JG, Yin B, Liu L, Lu YP, Geng DY, Tian WZ. Imaging features of pilocytic astrocytoma in cerebral ventricles. *Clin Neuroradiol.* 2016; 26:341-346.
6. Smith AB, Smirniotopoulos JG, Horkanyne-Szakaly I. Intraventricular neoplasms: Radiologic-pathologic correlation. *Radiographics.* 2013; 33:21-43.
7. Ostrom QT, Cioffi G, Gittleman H, Patil N, Waite K, Kruchko C, Barnholtz-Sloan JS. CBTRUS Statistical Report: Primary Brain and Other Central Nervous System Tumors Diagnosed in the United States in 2012-2016. *Neuro Oncol.* 2019; 21(Supplement 5):v1-v100.
8. Collins VP, Jones DT, Giannini C. Pilocytic astrocytoma: pathology, molecular mechanisms and markers. *Acta Neuropathol.* 2015; 129:775-788.

Received August 6, 2020; Revised October 5, 2020; Accepted October 8, 2020.

**Address correspondence to:*

Zhenggang Xiong, Division of Neuropathology, Department of Pathology and Laboratory Medicine, Robert Wood Johnson Medical School and University Hospital, Rutgers University, 125 Paterson Street, MEB 231, New Brunswick, NJ 08903, USA.

E-mail: xz460@rwjms.rutgers.edu

Released online in J-STAGE as advance publication October 9, 2020.