

# Fragile X associated neuropsychiatric disorders in a male without FXTAS

Ana María Cabal-Herrera<sup>1,2</sup>, Wilmar Saldarriaga-Gil<sup>2</sup>, Maria Jimena Salcedo-Arellano<sup>1,3</sup>, Randi J Hagerman<sup>1,3</sup>

<sup>1</sup> Medical Investigation of Neurodevelopmental Disorders (MIND) Institute, University of California Davis Health, Sacramento, CA, USA;

<sup>2</sup> School of Medicine, Universidad del Valle, Cali, Colombia;

<sup>3</sup> Department of Pediatrics, University of California Davis School of Medicine, Sacramento, CA, USA.

**SUMMARY** Fragile X syndrome (FXS) is the most common inherited cause of intellectual disability and autism spectrum disorder. In most cases, it is due to an expansion of the CGG triplet to more than 200 repeats within the promoter region of the *FMR1* gene. In the premutation (PM) the trinucleotide is expanded to 55-200 repeats. PM carriers can present with disorders associated with the PM including fragile X-associated tremor/ataxia syndrome (FXTAS) and fragile X-associated ovarian insufficiency (FXPOI). Recently fragile X-associated neuropsychiatric disorders (FXAND) was proposed as an umbrella term to include the neuropsychiatric disorders that are more prevalent in PM carriers compared to the general population such as anxiety, depression, chronic fatigue, alcohol abuse, and psychosis, among others. The patient in our study was evaluated by a team of clinicians from the University del Valle in Cali who traveled to Ricaurte, a Colombian town known for being a genetic geographic cluster of FXS. A detailed medical history was collected and complete physical, neurological and psychiatric evaluations were performed in addition to molecular and neuroradiological studies. We report the case of a 78-year-old man, PM carrier, without FXTAS whose main clinical presentation consists of behavioral changes and psychosis. Brain imaging revealed white matter lesions in the periventricular region and mild cerebral atrophy. Although anxiety and depression are the most common neuropsychiatric manifestations in PM carriers, it is important to perform a complete psychiatric evaluation since some patients may present with behavioral changes and psychosis.

**Keywords** fragile X mental retardation 1 gene, fragile X-associated neuropsychiatric disorders, premutation, FXAND, psychosis

## 1. Introduction

Fragile X Syndrome (FXS) is the most common inherited cause of intellectual disability and autism spectrum disorder (ASD) and is caused in the majority of cases by an expansion of the CGG repeat to > 200 repeats, in the 5' untranslated region of the fragile X mental retardation (*FMR1*) gene on the X chromosome (Xq27.3). This expansion, called the full mutation, leads to methylation of the promoter and low or absent levels of the *FMR1* protein (FMRP) (1). Individuals with FXS present with intellectual disability of varying degrees and, approximately 50-60% present with ASD. Common phenotypical features include an elongated face, prominent ears, and macroorchidism in males (2). The normal number of CGG repeats is < 40 repeats, 41-54 CGG repeats are considered the gray zone, and 55-

200 is considered the premutation (PM) (3). PM carriers are known to develop *FMR1* associated disorders such as fragile X-associated tremor/ataxia syndrome (FXTAS) which is a late-onset neurodegenerative disease with varying clinical manifestations including intention tremor, cerebellar ataxia, neuropathic pain, parkinsonism, memory, and executive function deficits among others (4). Fragile X-associated premature ovarian insufficiency (FXPOI) is another premutation disorder in approximately 20% of women with the premutation and is characterized by amenorrhea at an age earlier than 40 years (5).

Over time, neuropsychiatric manifestations in PM carriers with and without FXTAS have been reported including depression, anxiety, attention-deficit/hyperactivity disorder (ADHD), and insomnia (6-9). A new clinical term has been proposed in order to raise

awareness of the neuropsychiatric manifestations in PM carriers, fragile X-associated neuropsychiatric disorders (FXAND) (6). Although some studies have not found an increased risk of neuropsychiatric disorders in carriers (10,11), the majority of controlled studies have found significantly higher rates of neuropsychiatric disorders in carriers including depression, anxiety, ADHD, social phobia, chronic fatigue and personality traits such as those present in obsessive-compulsive disorder (OCD) (12-20). A recent blinded study from a large population associated with a health care program, Marshfield, demonstrated several psychiatric problems at a much higher rate in premutation carriers compared to controls (21). An increase in alcohol consumption and psychoactive substance abuse among PM carriers has been reported which is detrimental and has been shown to accelerate neurodegeneration (22-25). Since the proposal of FXAND as an umbrella term for neuropsychiatric manifestations in PM carriers, there have been two case reports published reporting patients who presented mainly with behavioral and psychiatric manifestations exemplifying FXAND as a condition that is separate from the other well-known premutation disorders (26,27).

Here, we report the case of a male PM carrier without FXTAS whose primary presentation consists of neuropsychiatric manifestations and therefore contributes to cases of PM carriers who could be categorized under FXAND. To date, only two cases that exemplify FXAND have been published. This case adds to the varied neuropsychiatric manifestations patients present with, including psychosis.

## 2. Case Report

This patient was evaluated in one of the medical brigades done in Ricaurte, a Colombian town known for being a genetic geographic cluster of FXS (Saldarriaga 2018). A detailed medical history was collected and physical, psychiatric, and neurological examinations were completed. The Scale for the Assessment and Rating of Ataxia (SARA) (28) and the Fahn-Tolosa Marin Clinical Rating Scale for Tremor (FTM) (29) were applied for the evaluation of clinical signs of FXTAS. Genetic testing results were obtained from previous research work done by Saldarriaga and colleagues in 2018 (30). The patient signed an informed consent to have his case history and neurological imaging published. Here, we describe the patient's medical history, neuropsychiatric symptoms, and findings on medical and imaging evaluations.

This is the case of a 78-year-old man, diagnosed as a PM carrier with 61 CGG repeats, who presented with a longstanding history of alcohol abuse, irritability and in the past 3 years delusional jealousy, depression and aggressive behavior. His birth history was unremarkable and he didn't present any medical condition during

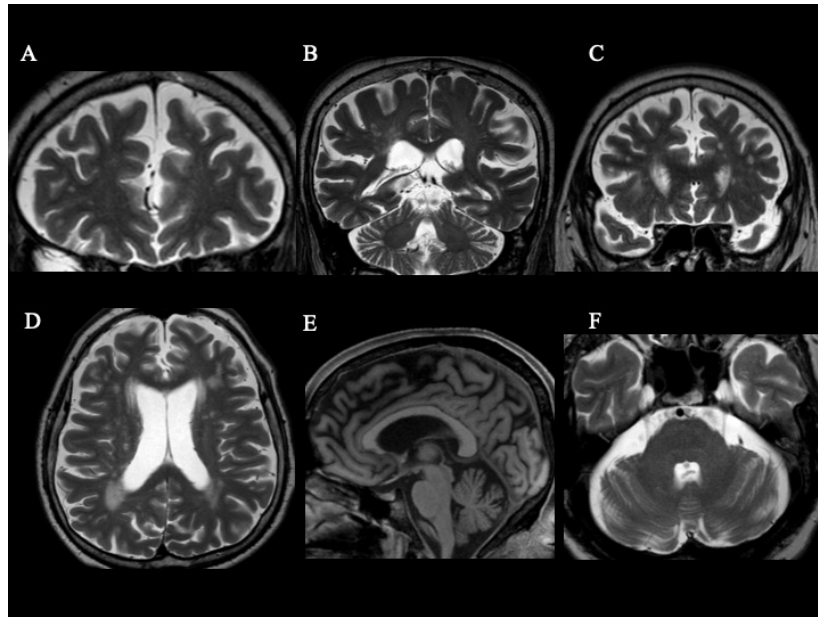
childhood. He did not report any learning difficulty at school nor problems with attention or ADHD symptoms.

At the age of 30, he started working as a boatman and began drinking alcohol almost daily for the subsequent 38 years. He reported he regularly drank 2-5 bottles (375 mL) of brandy or 20 beers throughout the day. He would on some occasions spend all his salary on drinking during payday. He experienced anxiety only on the days when he didn't drink alcohol. He didn't feel guilty about his alcohol consumption but was asked by doctors and family members to reduce consumption. He stopped drinking at the age of 68 when he was diagnosed with hypertension and was advised to quit his drinking habits. He denied the consumption of any nicotine product and denied the consumption of any psychoactive substance.

Three years ago he started having delusional jealousy with fixed ideas about his wife, a 71-year-old woman, being unfaithful, and having secret codes with her lovers at night. He would awaken at 1 am due to sounds he related to lovers coming for his wife, such as whistles, scratching at the door, and motorcycles. He then started sleeping with a machete (knife), hammers or a club in his nightstand to be prepared in case of an eventual confrontation. He would stand outside the house if he heard a motorcycle at night with his machete believing it was a lover approaching his wife. His family reported that since last year he locks all doors with chains and big locks and blocks the main door with sofas and chairs. He admitted to previously having thoughts about killing his wife due to her alleged unfaithfulness but claimed he no longer has these thoughts. His wife reported that he has never been jealous before nor aggressive. Six months ago they had to call the police because he was aggressive towards his wife and daughters but responded to verbal containment. The family members reported that when he becomes suspicious he threatens his wife. His wife also reported that although it has been years since they stopped having sexual encounters, on occasions he has made extravagant sexual proposals mentioning sexual positions she finds to be strange.

While experiencing the described personality changes, he has also become more irritable and the family stated that he at times becomes angry with otherwise innocent triggers, for example when lights are turned on or when his grandsons take his fruits. They claimed that when he gets upset, he presents with rigidity and clenches his teeth. Although he denies sleep problems, he remains vigilant throughout the night. He usually goes to bed at 8 pm but may wake up at 4 am to monitor for any sounds or movements in the surroundings. He reported recent feelings of hopelessness associated to his current worries. He met diagnostic criteria in DSM5 for depression.

During the interview, he denied any movement-related concerns, cognitive issues, or pain. He reported the onset



**Figure 1. Brain Magnetic Resonance Imaging: T2-weighted images (A, B, C, D, F) and T1-weighted image (E).** In this brain MRI, scattered white matter lesions affecting mainly frontal and parietal cortex are observed (A) (B) (C). Periventricular white matter lesions are also observed (B) (C) (D). There are white matter lesions affecting anterior and posterior horns bilaterally (D). Mild-moderate cerebral atrophy is evident in the frontal cortex (E). No white matter changes in the corpus callosum were observed, splenium sign was not present (E). No white matter changes in the middle cerebellar peduncles were observed (F).

of progressive hearing loss 5 years ago that has not been documented clinically nor treated with aides.

Current medications include monthly cobalamin, gemfibrozil, metformin for diabetes type 2 diagnosed in 2001, enalapril, and nifedipine for hypertension. He was prescribed quetiapine 25 mg/night 5 months ago but only took it once, suspending it due to somnolence. Five months ago his wife started giving him non-prescribed amitriptyline 50 mg at night powdered and hidden with his night time coffee. His daughters and wife reported that since he has been taking amitriptyline, he has been less aggressive, sleeps better and has stopped sleeping with a weapon next to him, although he has continued to lock the doors at night.

On neurological exam, there was no tremor with finger to nose touching, no rest tremor was evident and he was able to perform tandem gait without difficulty. He had normal evaluation when applying both SARA, score 1/40, and FTM scales. Vibration and pinprick evaluation were normal in all extremities. He did not have any primitive reflexes and his strength was normal in all extremities. There was bilateral hearing loss which was more prominent in his right ear. He scored 27/30 in the Mini-Mental State Examination (MMSE). During the examination, there was a pause for coffee when the examiners could observe the patient holding a cup and handling utensils without difficulty and without tremor.

This patient's cerebral MRI showed mild frontal atrophy, mild ventriculomegaly and white matter disease in the periventricular regions (Figure 1). There was no evidence of symmetrical white matter hyperintensities in the middle cerebellar peduncles - (MCP) sign - nor

white matter lesions in the corpus callosum. No other abnormalities were observed.

The patient was seen in a medical team evaluation in 2019. He was prescribed quetiapine 25 mg/night and sertraline 50 mg in AM. Due to current traveling restrictions, a telemedicine follow-up was performed. The family reports issues with compliance to medications but improvement regarding his delusional thinking and sleep pattern. This patient does not meet diagnostic criteria for FXTAS and most of his symptoms involve neuropsychiatric problems: a history of alcohol abuse, delusional jealousy, irritability, depression, disinhibition and hearing loss. The hearing loss is associated with the premutation but his other symptoms are all related to FXAND exacerbated by long term alcohol abuse.

### 3. Discussion

Here, we present a case of an adult male PM carrier with a long history of alcohol abuse, irritability and recent development of delusions and behavioral changes. He does not meet the FXTAS diagnostic criteria in carriers of a *FMRI* premutation, only presenting one minor radiologic criteria (MRI white matter lesions in cerebral white matter) (4). Although hearing loss is associated with aging in premutation carriers his main clinical problem list is most consistent with the recently described FXAND umbrella of neuropsychiatric symptoms.

FXAND is a term that encompasses various neuropsychiatric conditions associated with fragile X PM carriers. In this patient his neuropsychiatric

symptoms are also associated with white matter disease on MRI but he does not meet criteria for FXTAS currently, such as intention tremor, cerebellar ataxia, and parkinsonian features (4).

Neuroradiological abnormalities have been widely described for PM carriers with FXTAS, consisting of white matter disease in the cerebrum and/or cerebellum, white matter hyperintensities in the middle cerebellar peduncles, known as the MCP sign, and in the splenium of the corpus callosum and brain atrophy (31). The MCP sign is present in approximately 60% of male patients with FXTAS and is part of the major diagnostic criteria for this condition (32,33). White matter abnormalities in PM carriers without FXTAS, such as in our patient, have also been described and it has therefore been proposed that white matter pathology may be the initial point in the pathophysiology of neurological symptoms of carriers and perhaps puts him at high risk to develop FXTAS in the future (34-36).

This patient presented a long-standing history, thirty-eight years, of alcohol abuse. Excessive alcohol consumption has been reported to be a common condition in PM carriers compared to controls (25), although some studies have shown alcohol consumption rates to be similar to family control groups (37). In 1994 Dorn *et al.* evaluated psychiatric and behavioral problems among fathers of women with the PM and found that the prevalence of alcohol abuse/dependence for male PM carriers was significantly higher compared to controls, exceeding as well the prevalence rate of alcohol abuse/dependence reported for first-degree relatives of known alcoholics in a previous study (25). It has been proposed that alcohol abuse and illicit drug use may be common among carriers due to co-occurring anxiety, depression and ADHD (6,38). This patient reported anxiety symptoms when not consuming alcohol which may be explained by alcohol withdrawal but may also indicate that his long-standing history of alcohol abuse may have masked an anxiety disorder. It is important to address substance abuse in PM carriers since it has deleterious effects in the brain. Excessive alcohol consumption has a negative effect in white matter integrity, myelination, and promotes a neuroinflammatory state, which aggravates the already present neuronal oxidative stress state present in aging carriers (6,39). PM carriers must be advised about the increased rate of neurodegeneration due to excessive alcohol consumption and an increased risk of developing FXTAS (22,40).

The main neuropsychiatric symptom reported by the family of this patient was his delusional disorder-jealous type. Psychotic symptoms have been reported at increased rates in PM carriers in some studies, although they have been reported less frequently compared to other disorders such as depression and anxiety. Hessel *et al.* reported a prevalence of 26% of psychoticism/psychosis in males with the PM. They found that

elevated levels of *FMRI* mRNA in PM carriers was significantly associated with increases in psychological symptoms, mainly obsessive-compulsive symptoms and psychoticism/psychosis in PM males with and without FXTAS (41,42). Our patient additionally presented with disinhibition, irritability, and behavioral changes which have been reported in PM carriers, especially in those with FXTAS (10,43). It is important to note that some studies have not found an elevated risk of significant psychiatric symptoms in asymptomatic males with the PM, but this conflicted evidence may be due to different methodological approaches used in the different studies (25,37).

Other neuropsychiatric disorders reported in PM carriers without FXTAS include anxiety, which is the most common neuropsychiatric problem encountered in PM carriers, and depression, occurring in approximately 40% of PM carriers (6).

Physicians need to be aware of neuropsychiatric symptoms in PM carriers. More studies and case reports are needed in order to delineate and further characterize FXAND. FXAND constitutes a separate entity and it is important for clinicians evaluating a carrier of the premutation to evaluate for psychiatric and cognitive issues, even in the absence of symptoms of the other well-known premutation disorders. FXAND was proposed as an umbrella term in order to raise awareness into the problems that fall under it. To date, there are only two published case reports of patients that exemplify this condition. In the case report by Santos and colleagues, they present a 26-year-old male with the premutation with depression, anxiety, and ASD (26). In the case by G Tan and colleagues, they present a female with the premutation and a complex neuropsychiatric history including anxiety, depression, substance abuse, and chronic pain (27). This case differs in that the main psychiatric symptom is psychosis manifested as delusional disorder-jealous type, and behavioral changes in an older patient with no signs and symptoms of FXTAS. The patient had been evaluated by psychiatrists and primary care providers who didn't associate his clinical picture to the *FMRI* premutation. It exemplifies a case that can fall under the diagnosis of FXAND as a different condition associated to the premutation that should be considered during the evaluation of a patient with the premutation.

Although the main neuropsychiatric manifestations in PM carriers are anxiety and depression it is important to perform a complete neurologic and psychiatric evaluation since there have been reports, such as in our patient, in which the primary manifestations are psychosis and behavioral changes.

#### Acknowledgements

This research was supported by the National Institute of Child Health and Human Development (NICHD) grant



R01 HD036071, the MIND Institute Intellectual and Developmental Disability Research Center U54 HD 079125. We thank the patient for his participation as well as his family. We thank the inhabitants of Ricourte for always opening their doors to us.

### Financial Disclosures

RJ Hagerman has received funding from Zynerba, Ovid and the Azrieli Foundation for carrying out treatment studies in patients with fragile X syndrome (FXS). She has also consulted with Fulcrum, Ovid and Zynerba regarding treatment studies in individuals with FXS.

### References

- Hagerman RJ, Berry-Kravis E, Hazlett HC, Bailey DB, Moine H, Kooy RF, Tassone F, Gantois I, Sonenberg N, Mandel JL, Hagerman PJ. Fragile X syndrome. *Nat Rev Dis Prim.* 2017; 3:17065.
- Ciaccio C, Fontana L, Milani D, Tabano S, Miozzo M, Esposito S. Fragile X syndrome: a review of clinical and molecular diagnoses. *Ital J Pediatr.* 2017; 43:39.
- Debrey SM, Leehey MA, Klepitskaya O, Filley CM, Shah RC, Kluger B, Berry-Kravis E, Spector E, Tassone F, Hall DA. Clinical phenotype of adult fragile X gray zone allele carriers: a case series. *Cerebellum.* 2016; 15:623-631.
- Hagerman RJ, Hagerman P. Fragile X-associated tremor/ataxia syndrome - features, mechanisms and management. *Nat Rev Neurol.* 2016; 12:403-412.
- Allen EG, Glicksman A, Tortora N, Charen K, He W, Amin A, Hipp H, Shubeck L, Nolin SL, Sherman SL. FXPOI: Pattern of AGG interruptions does not show an association with age at amenorrhea among women with a premutation. *Front Genet.* 2018; 9: 292.
- Hagerman RJ, Protic D, Rajaratnam A, Salcedo-Arellano MJ, Aydin EY, Schneider A. Fragile X-associated neuropsychiatric disorders (FXAND). *Front Psychiatry.* 2018; 9:564.
- Gossett A, Sansone S, Schneider A, Johnston C, Tassone F, Rivera SM, Seritan AL, Hessler D. Psychiatric disorders among women with the fragile X premutation without children affected by fragile X syndrome. *Am J Med Genet B Neuropsychiatr Genet.* 2016; 171:1139-1147.
- Bourgeois JA, Cogswell JB, Hessler D, Zhang L, Ono MY, Tassone F, Farzin F, Brunberg JA, Grigsby J, Hagerman RJ. Cognitive, anxiety and mood disorders in the fragile X-associated tremor/ataxia syndrome. *Gen Hosp Psychiatry.* 2007; 29:349-356.
- Cordeiro L, Abucayan F, Hagerman R, Tassone F, Hessler D. Anxiety disorders in fragile X premutation carriers: Preliminary characterization of probands and non-probands. *Intractable Rare Dis Res.* 2015; 4:123-130.
- Grigsby J, Brega AG, Bennett RE, Bourgeois JA, Seritan AL, Goodrich GK, Hagerman RJ. Clinically significant psychiatric symptoms among male carriers of the fragile X premutation, with and without FXTAS, and the mediating influence of executive functioning. *Clin Neuropsychol.* 2016; 30:944-959.
- Hunter JE, Allen EG, Abramowitz A, Rusin M, Leslie M, Novak G, Hamilton D, Shubeck L, Charen K, Sherman SL. No Evidence for a Difference in Neuropsychological Profile among Carriers and Noncarriers of the FMR1 Premutation in Adults under the Age of 50. *Am J Hum Genet.* 2008; 83:692-702.
- Jiraanont P, Sweha SR, AlOlaby RR, Silva M, Tang HT, Durbin-Johnson B, Schneider A, Espinal GM, Hagerman PJ, Rivera SM, Hessler D, Hagerman RJ, Chutabhakdikul N, Tassone F. Clinical and molecular correlates in fragile X premutation females. *eNeurologicalSci.* 2017; 7:49-56.
- Franke P, Leboyer M, Gänssicke M, Weiffenbach O, Biancalana V, Cornillet-Lefebvre P, Croquette MF, Froster U, Schwab SG, Poustka F, Hautzinger M, Maier W. Genotype-phenotype relationship in female carriers of the premutation and full mutation of FMR-1. *Psychiatry Res.* 1998; 80:113-127.
- Bourgeois JA, Seritan AL, Casillas EM, Hessler D, Schneider A, Yang Y, Kaur I, Cogswell JB, Nguyen DV, Hagerman RJ. Lifetime prevalence of mood and anxiety disorders in fragile X premutation carriers. *J Clin Psychiatry.* 2011; 72:175-182.
- L. Seritan A, A. Bourgeois J, Schneider A, Mu Y, J. Hagerman R, V. Nguyen D. Ages of onset of mood and anxiety disorders in fragile X premutation carriers. *Curr Psychiatry Rev.* 2013; 9:65-71.
- Roberts JE, Bailey Jr DB, Mankowski J, Ford A, Sideris J, Weisenfeld LA, Heath TM, Golden RN. Mood and anxiety disorders in females with the FMR1 premutation. *Am J Med Genet B Neuropsychiatr Genet.* 2009; 150B:130-139.
- Schneider A, Johnston C, Tassone F, Sansone S, Hagerman RJ, Ferrer E, Rivera SM, Hessler D. Broad autism spectrum and obsessive-compulsive symptoms in adults with the fragile X premutation. *Clin Neuropsychol.* 2016; 30:929-943.
- Farzin F, Perry H, Hessler D, Loesch D, Cohen J, Bacalman S, Gane L, Tassone F, Hagerman PJ, Hagerman RJ. Autism spectrum disorders and attention-deficit/hyperactivity disorder in boys with the fragile X premutation. *J Dev Behav Pediatr.* 2006; 27:S137-S144.
- Chonchaiya W, Au J, Schneider A, Hessler D, Harris SW, Laird M, Mu Y, Tassone F, Nguyen DV, Hagerman RJ. Increased prevalence of seizures in boys who were probands with the FMR1 premutation and co-morbid autism spectrum disorder. *Hum Genet.* 2012; 131:581-589.
- Summers SM, Cogswell J, Goodrich JE, Mu Y, Nguyen D V, Brass SD, Hagerman RJ. Fatigue and body mass index in the Fragile X premutation carrier. *Fatigue Biomed Heal Behav.* 2014; 2:64-72.
- Movaghgar A, Page D, Brilliant M, Baker MW, Greenberg J, Hong J, DaWalt LS, Saha K, Kuusisto F, Stewart R, Berry-Kravis E, Mailick MR. Data-driven phenotype discovery of FMR1 premutation carriers in a population-based sample. *Sci Adv.* 2019; 5:eaaw7195.
- Muzar Z, Adams PE, Schneider A, Hagerman RJ, Lozano R. Addictive substances may induce a rapid neurological deterioration in fragile X-associated tremor ataxia syndrome: A report of two cases. *Intractable rare Dis Res.* 2014; 3:162-165.
- Muzar Z, Lozano R, Schneider A, Adams PE, Faradz SMH, Tassone F, Hagerman RJ. Methadone use in a male with the FMRI premutation and FXTAS. *Am J Med Genet Part A.* 2015; 167:1354-1359.
- Martínez-Cerdeño V, Lechpammer M, Lott A, Schneider A, Hagerman R. Fragile X-associated tremor/ataxia syndrome in a man in his 30s. *JAMA Neurol.* 2015; 72:1070-1073.

25. Dorn MB, Mazzocco MM, Hagerman RJ. Behavioral and psychiatric disorders in adult male carriers of fragile X. *J Am Acad Child Adolesc Psychiatry.* 1994; 33:256-264.
26. Santos E, Emeka-Nwonovo C, Wang JY, Schneider A, Tassone F, Hagerman P, Hagerman RJ. Developmental aspects of FXAND in a man with the FMR1 premutation. *Mol Genet Genomic Med.* 2020; 8:e1050.
27. G Tan MM, S Dy JB, Salcedo-Arellano MJ, Tassone F, Hagerman RJ. Fragile X-Associated neuropsychiatric disorders: A case report. *Future Neurol.* 2019; 14. doi: 10.2217/fnl-2018-0040
28. Schmitz-Hübsch T. Scale for the assessment and rating of ataxia (SARA). In book: *Encyclopedia of Movement Disorders.* 2010; pp.95-99.
29. Jankovic J, Tolosa E. *Parkinson's Disease and Movement Disorders.* 6th Editio. Jankovic J, Tolosa E, editors. Baltimore: Williams & Wilkins; 2015.
30. Saldarriaga W, Forero-Forero JV, González-Teshima LY, Fandiño-Losada A, Isaza C, Tovar-Cuevas JR, Silva M, Choudhary NS, Tang HT, Aguilar-Gaxiola S, Hagerman RJ, Tassone F. Genetic cluster of fragile X syndrome in a Colombian district. *J Hum Genet.* 2018; 63:509-516.
31. Hocking DR, Loesch DZ, Trost N, Bui MQ, Hammersley E, Francis D, Tassone F, Storey E. Total and regional white matter lesions are correlated with motor and cognitive impairments in carriers of the FMR1 premutation. *Front Neurol.* 2019; 10:832.
32. Brown SSG, Stanfield AC. Fragile X premutation carriers: A systematic review of neuroimaging findings. *J Neurol Sci.* 2015; 352:19-28.
33. Hall DA, Birch RC, Anheim M, Jønch AE, Pintado E, O'Keefe J, Trollor JN, Stebbins GT, Hagerman RJ, Fahn S, Berry-Kravis E, Leehey MA. Emerging topics in FXTAS. *J Neurodev Disord.* 2014; 6:31.
34. Filley CM, Brown MS, Onderko K, Ray M, Bennett RE, Berry-Kravis E, Grigsby J. White matter disease and cognitive impairment in FMR1 premutation carriers. *Neurology.* 2015; 84:2146-2152.
35. Wang JY, Hagerman RJ, Rivera SM. A multimodal imaging analysis of subcortical gray matter in fragile X premutation carriers. *Mov Disord.* 2013; 28:1278-1284.
36. Famula JL, McKenzie F, McLennan YA, Grigsby J, Tassone F, Hessl D, Rivera SM, Martinez-Cerdeño V, Hagerman RJ. Presence of middle cerebellar peduncle sign in FMR1 premutation carriers without tremor and ataxia. *Front Neurol.* 2018; 9:695.
37. Kogan CS, Turk J, Hagerman RJ, Cornish KM. Impact of the fragile X mental retardation 1 (FMR1) gene premutation on neuropsychiatric functioning in adult males without fragile X-associated tremor/ataxia syndrome: A controlled study. *Am J Med Genet Part B Neuropsychiatr Genet.* 2008; 147B:859-872.
38. Polussa J, Schneider A, Hagerman R. Molecular advances leading to treatment implications for fragile X premutation carriers. *Brain Disord Ther.* 2014; 3. pii: 1000119.
39. Alfonso-Loeches S, Pascual-Lucas M, Blanco AM, Sanchez-Vera I, Guerri C. Pivotal role of TLR4 receptors in alcohol-induced neuroinflammation and brain damage. *J Neurosci.* 2010; 30:8285-8295.
40. Loesch DZ, Sherwell S, Kinsella G, Tassone F, Taylor A, Amor D, Sung S, Evans A. Fragile X-associated tremor/ataxia phenotype in a male carrier of unmethylated full mutation in the FMR1 gene. *Clin Genet.* 2012; 82:88-92.
41. Hessl D, Tassone F, Loesch DZ, *et al.* Abnormal elevation of FMR1 mRNA is associated with psychological symptoms in individuals with the fragile X premutation. *Am J Med Genet Part B Neuropsychiatr Genet.* 2005; 139B:115-121.
42. Winarni TI, Schneider A, Ghaziuddin N, Seritan A, Hagerman RJ. Psychosis and catatonia in fragile X: case report and literature review. *Intractable Rare Dis Res.* 2015; 4:139-146.
43. Seritan A, Cogswell J, Grigsby J. Cognitive dysfunction in FMR1 premutation carriers. *Curr Psychiatry Rev.* 2013; 9:78-84.

Received March 6, 2020; Revised May 13, 2020; Accepted May 16, 2020.

\*Address correspondence to:

Ana María Cabal-Herrera, School of Medicine, Universidad del Valle, Cali, Colombia.

E-mail: ana.cabal@correounivalle.edu.co

Released online in J-STAGE as advance publication May 24, 2020.