

A curious case of disseminated cysticercosis in an immunocompetent adult

Azka Latif*, Vikas Kapoor, Brett Weum, Mohsin Mirza, Manasa Velagapudi

CHI Health Creighton University Medical Center - Bergan Mercy, Omaha, NE, USA.

Summary

Cysticercosis is an infection with the larval stage of *Taenia Solium* which is estimated to affect over 50 million people worldwide. We report a case of disseminated cysticercosis in an immunocompetent 68-year-old male who presented with back pain, presumed to be musculoskeletal in nature initially. Magnetic-resonance-imaging of the lumbar spine revealed intramuscular (paraspinous and psoas muscles) cysts, innumerable small cystic lesions bilaterally throughout the cerebellar and cerebral hemispheres, midbrain, and right ventricle suggestive of cysticercosis. Treatment with albendazole with dexamethasone for 3 months led to resolution of the cysts with complete resolution of symptoms. Despite its importance, current data on prevalence of this infection, disease burden and the incidence of hospitalization remains incomplete. Mandatory reporting of diagnosis would enable complete understanding of epidemiology of the disease. In this case we have emphasized the importance of early diagnosis of a systemic condition that could have caused serious implications if left untreated.

Keywords: Disseminated, cysticercosis, immunocompetent

Cysticercosis is an infection with the larval stage of pork tapeworm, *Taenia solium*. It is estimated to affect over 50 million people worldwide (1,2). It is common among immigrant population in the United States (US), with > 2,000 cases per year leading to hospital charges of nearly 100\$ million per year. Endemic regions include Sub-Saharan Africa, Latin America and some parts of Asia (3-6). The usual sites of involvement are the central nervous system (97.46%), the eye (1.4%), skeletal, heart muscles, skin and subcutaneous tissue (1.14%) (7).

Here, we report an uncommon case of disseminated cysticercosis (DCC) in immunocompetent adult. A 68-year-old immigrant man presented to primary care clinic with chronic back pain with an acute worsening in the past four weeks. His pain started in his left hip with radiation to left lower leg along with associated numbness and tingling, and weakness. He denied any fever, chills, saddle anesthesia, bladder incontinence, or bowel incontinence. He has no other medical comorbidities. Review of symptoms was non-significant.

Vital signs were normal. On physical exam he had an antalgic gait with tenderness along his left paraspinal muscles with limited extension and flexion of the left leg. The straight leg test was performed and was positive at 20 degrees in addition to decreased strength (4/5) in his hip flexors and quadriceps in the left leg. Complete blood count with differential and basic metabolic panel were within normal limits. Further workup with magnetic resonance imaging (MRI) of the lumbar spine revealed L5 disc protrusion compressing the nerve root in addition to intramuscular (paraspinous and psoas muscles) cysts suggestive of cysticercosis (Figure 1A). MRI of the brain revealed innumerable small cystic lesions bilaterally throughout the cerebellar and cerebral hemispheres, midbrain, and right ventricle consistent with neurocysticercosis in the vesicular stage (Figure 1B). Cysts were additionally seen in the posterior neck musculature and the right temporalis muscle. He was started on albendazole 400 mg twice daily with dexamethasone 6mg twice daily for 3 months which he tolerated well. Repeat MRI of brain and lumbar spine two months after his first MRI showed resolution of the cysts (Figure 1C) with complete resolution of symptoms. The Center for Disease Control and prevention has designated cysticercosis as "one of the five neglected parasite infections". Likewise, the World Health Organization has

*Address correspondence to:

Dr. Azka Latif, CHI Health Creighton University Medical Center - Bergan Mercy, 7500 Mercy Road, Omaha, NE 68124, USA.

E-mail: azkalatif@creighton.edu

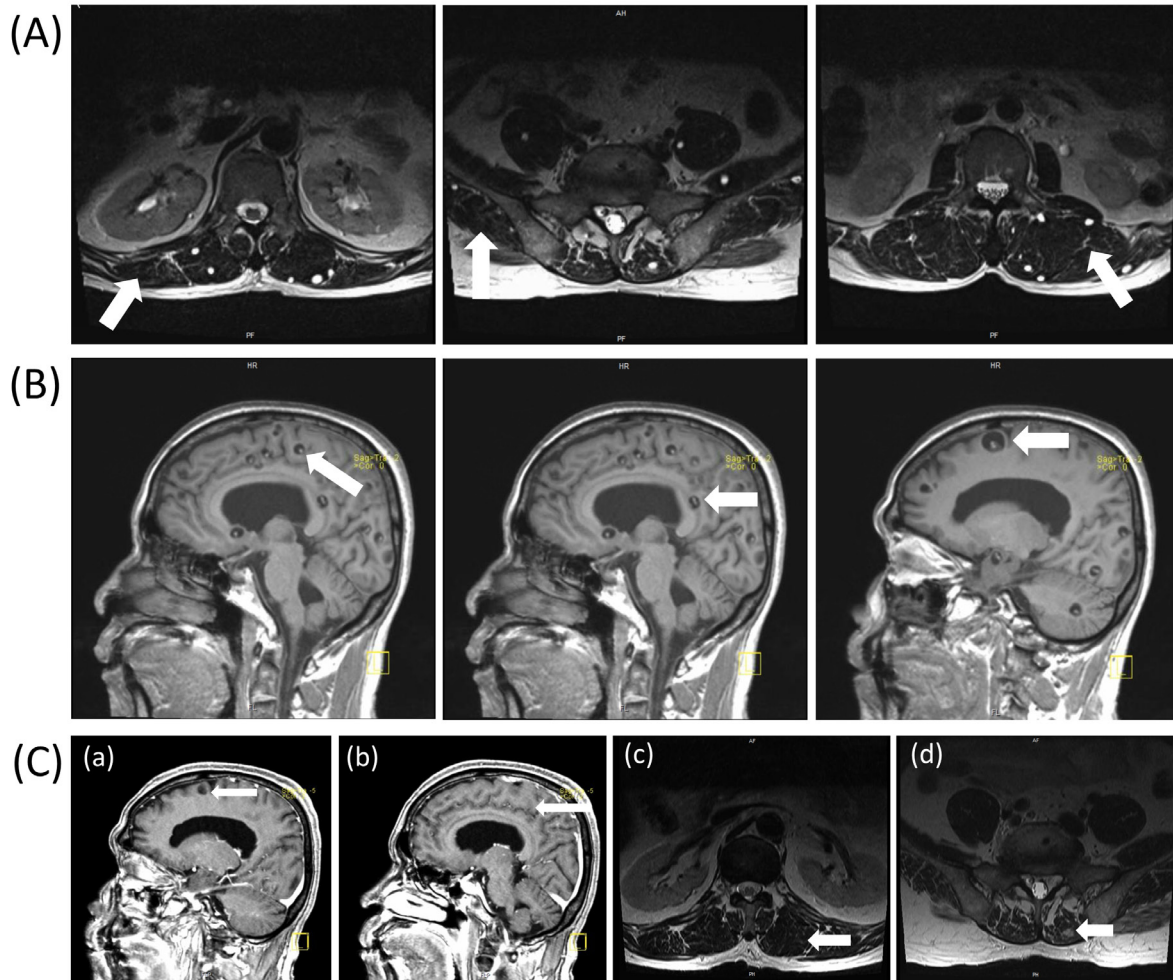


Figure 1. (A) Lumbar MRI shows innumerable intramuscular cysts most suggestive of cysticercosis (red arrows); (B) Brain MRI numerous to count small cystic lesions throughout the bilateral cerebral and cerebellar hemispheres, midbrain, and right ventricle; (C) Brain MRI shows interval decrease in size of the innumerable small cystic lesions throughout the bilateral cerebral and cerebellar hemispheres (a, b); No edema surrounding enhancing lesions. Lumbar MRI shows significant interval decrease in size and number of the innumerable intramuscular cysts (c, d).

designated it as "one of the seventeen neglected tropical diseases" worldwide. A survey was conducted in ED of eleven institutions throughout the US. It was noticed 2.1% of 1,801 patients presenting with seizures were diagnosed with neurocysticercosis. Despite its importance, current data on prevalence of this infection, disease burden and the incidence of hospitalization remains incomplete. Mandatory reporting of diagnosis would enable complete understanding of epidemiology of the disease. In this case we have tried to emphasize the importance of early diagnosis of a systemic condition that could have caused serious implications if left untreated.

DCC is a condition with multiple organ involvement. Although cysticercosis is common, DCC is an uncommon manifestation. It is usually seen in immunocompromised individuals, DCC in immunocompetent state is extremely rare with less than 50 cases being reported in literature, the majority being seen in India. Management of DCC includes albendazole (15 mg/kg/day) for 28 days or praziquantel (10-15 mg/kg/day) for 7-21 days. Further,

symptomatic treatment of seizures with antiepileptics and glucocorticoids to decrease the host response and inflammatory changes is recommended.

Our patient was immunocompetent who initially presented with back pain, which was presumed to be musculoskeletal in nature. He was being treated with pain medications along with physical therapy for 4 weeks when he presented again with antalgic gait. At that time spine MRI was done for further evaluation which showed multiple paraspinous and psoas muscle cysts. This emphasize the fact that a high suspicion of disseminated cysticercosis should be considered in immigrant population. When there is suspicion of cysticercosis, a whole body MRI should be done for detection of disease burden and to plan the appropriate therapy accordingly.

References

1. Debaq G, Moyano LM, Garcia HH, Boumediene F,

- Marin B, Ngoungou EB, Preux PM. Systematic review and meta-analysis estimating association of cysticercosis and neurocysticercosis with epilepsy. *PLoS Negl Trop Dis.* 2017; 11:e0005153.
2. Garcia HH, Nash TE, Del Brutto OH. Clinical symptoms, diagnosis, and treatment of neurocysticercosis. *Lancet Neurol.* 2014; 13:1202-1215.
 3. Kamal MM, Grover SV. Cytomorphology of subcutaneous cysticercosis. A report of 10 cases. *Acta Cytol.* 1995; 39:809-812.
 4. Kraft R. Cysticercosis: an emerging parasitic disease. *Am Fam Physician.* 2007; 76:91-96.
 5. Naik D, Srinath M, Kumar A. Soft tissue cysticercosis-Ultrasonographic spectrum of the disease. *Indian J Radiol Imaging.* 2011; 21:60-62.
 6. Prasad KN, Prasad A, Verma A, Singh AK. Human cysticercosis and Indian scenario: A review. *J Biosci.* 2008. 33:571-582.
 7. Ndimubanzi PC, Carabin H, Budke CM, Nguyen H, Qian YJ, Rainwater E, Dickey M, Reynolds S, Stoner JA. A systematic review of the frequency of neurocysticercosis with a focus on people with epilepsy. *PLoS Negl Trop Dis.* 2010. 4:e870.

(Received August 14, 2019; Revised November 20, 2019; Accepted November 23, 2019)