

Progressive disseminated histoplasmosis in an immunocompetent adult: A case report

Nitesh Kumar Bauddha, Ranveer Singh Jadon*, Saikat Mondal, NK Vikram, Rita Sood

Department of Medicine, All India Institute of Medical Sciences (AIIMS), New Delhi, India.

Summary

Histoplasmosis is a systemic fungal infection caused by *Histoplasma capsulatum* which occurs endemically in some parts of the world like North and Central America particularly in Mississippi and Ohio River valleys, but is uncommon in India. Progressive disseminated form of histoplasmosis (PDH) usually occurs in the immune-compromised hosts especially in HIV positive population. In PDH any organ can be involved like lung, liver, spleen, brain, adrenals etc. Involvement of oral cavity and buccal mucosa in PDH is common but pharyngeal involvement is rare. We here report a case of progressive disseminated histoplasmosis with pharyngeal involvement in an immunocompetent male from non-endemic area. This case presented to us with history of long duration fever and we found the etiology by giving due significance to a trivial symptom and thorough evaluation of the same. Etiology was found as disseminated histoplasmosis, which is not a common disease. We treated him initially with amphotericin-B then subsequently with itraconazole for one year. He recovered fully over the period of one year with the given treatment. This case report emphasizes that disseminated histoplasmosis should be considered one differential diagnosis in case of long duration of fever, even in an immunocompetent patient. It also emphasizes that in evaluation of a case of long duration of fever, even a trivial symptom is very crucial, which may direct towards the diagnosis.

Keywords: Progressive disseminated histoplasmosis, immunocompetent, pharyngeal histoplasmosis, *Histoplasma capsulatum*, fever of unknown origin

1. Introduction

Histoplasmosis is a systemic fungal infection caused by *Histoplasma capsulatum* which occurs endemically in some parts of the world, but is uncommon in India (1). *Histoplasma capsulatum* is endemic in many parts of the world like North and Central America particularly in Mississippi and Ohio River valleys. Travel to these endemic regions is an important predisposing factor for occurrence of histoplasmosis in individuals belonging to non-endemic areas (1). Soil contaminated with bird droppings acts as the main environmental reservoir for

this fungi. It exists in the environment in mold form as well as in forms of microconidia and macroconidia, while in tissue it exists as yeast form. The microconidia are the infectious form and inhalation of these is the major route of infection. Involvement of individuals in activities that disturb the soil and bird droppings like excavation and construction activities in the endemic regions expose individuals to the microconidia of the fungi (1). Progressive disseminated form of histoplasmosis (PDH) usually occurs in the immune-compromised hosts especially in the HIV positive population (2). Involvement of oral cavity and buccal mucosa in PDH is common but pharyngeal involvement is rare.

We here report a case of progressive disseminated histoplasmosis with pharyngeal involvement in an immunocompetent male from non-endemic area.

2. Case Report

A 54 year old, previously healthy male from Agra,

Released online in J-STAGE as advance publication May 15, 2018.

*Address correspondence to:

Dr. Ranveer Singh Jadon, Department of Medicine, All India Institute of Medical Sciences (AIIMS), Room No.21, SRB Lab, 3rdFloor, Teaching Block, New Delhi 110029, India.
E-mail: rsjadonaiims@gmail.com

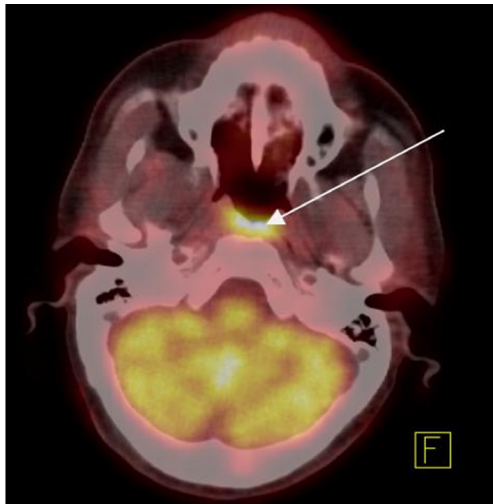


Figure 1. FDG-PET scan showing significantly increased FDG uptake in the posterior pharyngeal wall.

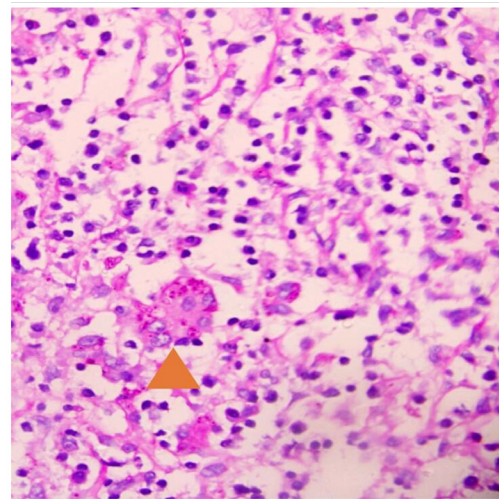


Figure 2. Yeasts of histoplasma are seen extracellularly as well as inside the giant cells under 40× magnification in the biopsy specimen taken from pharynx (Periodic acid Schiff staining with diastase).

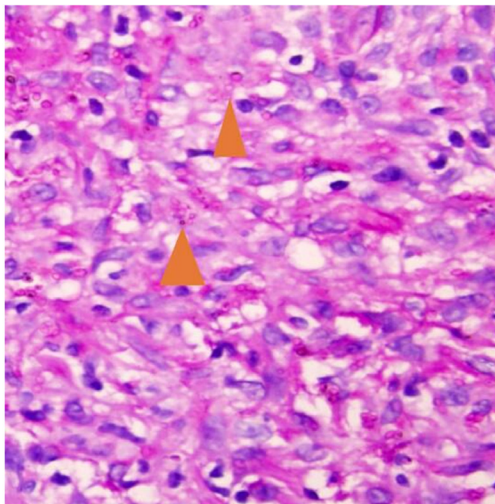


Figure 3. Yeast form of histoplasma is seen under 40× magnification in the biopsy specimen taken from pharynx (Periodic acid Schiff staining with diastase).

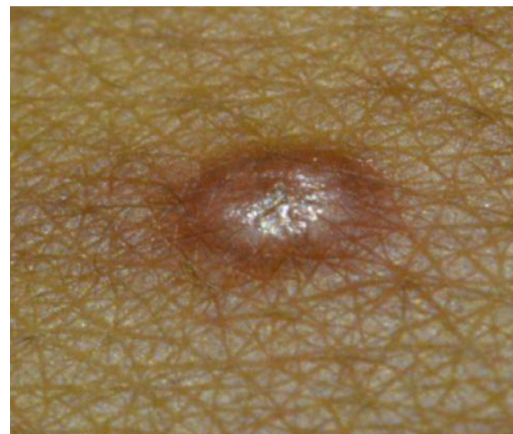


Figure 4. Nodular skin lesion over chest developed after starting amphotericin B.

Northern India was admitted to us with complaints of intermittent and moderate to high-grade fever of four months duration. Fever was associated with mild dry cough, night sweats, anorexia and weight loss of about five kg over four months. There were no musculoskeletal, abdominal or genitourinary symptoms. He was not a diabetic and had been treated for pulmonary tuberculosis 30 years ago. One month prior to presentation to us, he was prescribed empirical anti tubercular therapy, which he took for around 3 weeks without any relief and stopped by himself.

His general physical examination was unremarkable, except for presence of mild pallor. Systemic examination revealed mild hepatosplenomegaly. Laboratory parameters showed mild anaemia (Hb – 10.1 gm/dL) with normal ESR. His blood glucose was in normal range, liver and kidney function tests were also normal with normal albumin to globulin ratio. Investigations for malaria, kala-azar, brucellosis, HIV and autoimmune

markers were negative. Bone marrow examination showed reactive changes with no evidence of Leishmania Donovanii (LD) bodies, granulomas and abnormal cells. Contrast enhanced CT scan of thorax and abdomen revealed hepato-splenomegaly with no focal lesions and echocardiography showed no vegetations. During hospitalisation patient continued to have intermittent spikes of moderate grade fever. On further evaluation, his FDG Positron Emission Tomography (PET) scan (Figure 1) showed uptake in the region of posterior pharyngeal wall which was reported as likely to be physiological. Around the same time, patient developed mild throat discomfort and pain during swallowing. His throat examination showed mild congestion on posterior pharyngeal wall and soft palate. He received symptomatic treatment with decongestants but his symptoms did not improve and subsequently ENT consultation was sought. On endoscopic examination, he was found to have unhealthy mucosa of posterior

pharyngeal wall and soft palate with multiple whitish ulcers. Multiple biopsies were taken from these ulcers. Histopathological examination of these biopsy specimens was done initially with hematoxylin and eosin stain followed by Gomori methenamine silver and Periodic acid Schiffs with diastase (PAS-D) stain, which revealed multiple, small yeast like fungus both intra and extracellularly, highly suggestive of *Histoplasma capsulatum* (Figures 2 and 3). Later on, the culture from the same specimen grew *Histoplasma capsulatum*.

Patient was started on liposomal amphotericin B (3 mg/kg/day) after which the fever and throat symptoms disappeared within a week. After three days since starting the treatment, patient developed pruritic papulo-nodular rash over his neck and chest (Figure 4). Biopsy from these skin lesions was also suggestive of *Histoplasma capsulatum*. Patient responded well to liposomal amphotericin B and after two weeks was switched to oral itraconazole therapy (200 mg BD). Patient tolerated the drugs well and continued to improve over the next few days. After six months of treatment, he continued to be afebrile and gained weight. He was given oral itraconazole for one year, and he recovered fully; subsequently his medication was stopped.

3. Discussion

Histoplasmosis is a systemic fungal infection caused by dimorphic fungi *Histoplasma Capsulatum* (1). Activities that disturb the soil and bird droppings like excavation and construction activities in the endemic regions expose individuals to the spores (microconidia) of the fungi (1). Only less than one percent of exposed individuals develop disease and the development of the symptoms depends on the level of exposure as well as the immune status of the person exposed (2). Histoplasmosis can be clinically classified into pulmonary histoplasmosis and extrapulmonary or disseminated histoplasmosis. Acute pulmonary histoplasmosis occurs after initial infection with this fungus, mostly in children. It is usually a self-limited illness which mimics viral respiratory tract infections with fever, malaise, arthralgias, cough, and chest pain. Chronic cavitary form of pulmonary histoplasmosis occurs mainly in individuals with pre-existing lung diseases especially emphysematous lungs. The presentation is very similar to pulmonary tuberculosis as patients usually have fever, malaise, anorexia and weight loss with cough, expectoration, dyspnoea and haemoptysis and the chest X ray shows large cavitary lesions and fibrosis (1). In individuals with compromised immunity (diabetes, HIV positive patients with CD4 < 150, alcoholics and those on immunosuppressive drugs) the fungus disseminates to various sites causing the life threatening form of disease called PDH (1). The involvement of two or more sites

by the fungus defines the diagnosis of disseminated histoplasmosis, which in our case was seen as involvement of oropharynx and skin. Disseminated form of histoplasmosis can present as acute, subacute or chronic PDH (1). PDH is uncommon in India and until now less than 200 cases have been reported. Most of these cases belong to the Eastern and North-Eastern states of India, mostly from West Bengal and Assam (2-5). Our patient belonged to Agra (Northern India) from where PDH has been reported very rarely. It is very likely that many cases remain undiagnosed due to non-availability of specific diagnostic tests or misdiagnosed as tuberculosis which is so rampant in India. The under reporting of cases is also a reason behind the meager data available in India for histoplasmosis.

Nearly 75-80% cases of PDH present as fever of unknown origin with constitutional symptoms, anorexia and weight loss (3-5). This fungus can disseminate from lungs to virtually every organ of the body and commonly spreads to liver, spleen, adrenal glands, lymph nodes, bone marrow and gastro intestinal tract. Hepatosplenomegaly is found in nearly 50 % of patients (3-5) and gives an early clue towards dissemination of the disease. Respiratory symptoms and lymphadenopathy is also common. Since clinically histoplasmosis mimics disseminated tuberculosis, it is not uncommon for these patients to receive empirical anti-tubercular therapy before being diagnosed as histoplasmosis, thus delaying the diagnosis (3).

Oropharyngeal involvement is seen in 30-40% of cases of PDH and most commonly involves buccal mucosa (54.8%) followed by tongue and palate (6). Involvement of pharynx and larynx is rare. Lesions may notoriously mimic malignancy both clinically and pathologically and pose a great challenge for the clinicians in diagnosis and management (7). Many patients having oropharyngeal disease also have simultaneous involvement of adrenal glands which can present as life threatening adrenal insufficiency.

Diagnosis of PDH relies mainly on the histopathology of the biopsy from affected tissues with a sensitivity of 75-80% (8). Culture remains the gold standard for diagnosis of histoplasmosis with sensitivity of 74% with highest yield from bone marrow and blood (8). Measurement of histoplasma antigen in serum and urine is a very useful test as it has high sensitivity of 94% and it can be used to monitor the response to therapy (8).

Treatment of PDH involves administration of liposomal amphotericin B (3-5 mg/kg/day) for 2 weeks followed by a maintenance therapy with oral itraconazole 200 mg BD for at least one year with regular monitoring of histoplasma antigen level in serum or urine (8). We were not able to monitor histoplasma antigen levels due to non-availability of this test at our institute.

Thus PDH though uncommon, is not rare in India and needs to be considered as a differential diagnosis in a case of fever of unknown origin even in

immunocompetent adults belonging to non-endemic regions. Although individually both the throat findings as well as the findings in the FDG PET scan were subtle, correlating them and subjecting the patient to further evaluation proved vital. This highlights the fact that in a case of fever of unknown origin subtle symptoms and signs should not be considered insignificant and should be evaluated thoroughly, as these could be potential diagnostic clues (PDCs). However, absent initially these PDCs could appear any time during the course of illness and should be pursued further.

Acknowledgements

We would like to thank Dr. Alok Thakkar (Professor, Dept of ENT AIIMS New Delhi) for his precious clinical inputs in diagnosing the case and for providing images of throat examination. We would also like to thank Dr. M C Sharma (Professor Dept of Pathology AIIMS New Delhi) for helping in diagnosis and providing images of pathological examination of specimens.

References

1. Kauffman CA. Histoplasmosis: A clinical and laboratory update. *Clin Microbiol Rev.* 2007; 20:115-132.
2. Goswami RP, Pramanik N, Banerjee D, Raza MM, Guha SK, Maiti PK. Histoplasmosis in eastern India: The tip of the iceberg? *Trans R Soc Trop Med Hyg.* 1999; 93:540-542.
3. Gopalakrishnan R, Nambi PS, Ramasubramanian V, Abdul Ghafur K, Parameswaran A. Histoplasmosis in India: Truly uncommon or uncommonly recognised? *J Assoc Physicians India.* 2012; 60:25-28.
4. Subramanian S, Abraham OC, Rupali P, Zachariah A, Mathews MS, Mathai D. Disseminated histoplasmosis. *J Assoc Physicians India.* 2005; 53:185-189.
5. Deodhar D, Frenzen F, Rupali P, David D, Promila M, Ramya I, Seshadri MS. Disseminated histoplasmosis: A comparative study of the clinical features and outcome among immunocompromised and immunocompetent patients. *Natl Med J India.* 2013; 26:214-215.
6. Antonello VS, Zaltron VF, Vial M, Oliveira FM, Severo LC. Oropharyngeal histoplasmosis: Report of eleven cases and review of the literature. *Rev Soc Bras Med Trop.* 2011; 44:26-29.
7. Viswanathan S, Chawla N, D'Cruz A, Kane SV. Head and neck histoplasmosis-A nightmare for clinicians and pathologists! Experience at a tertiary referral cancer centre. *Head Neck Pathol.* 2007; 1:169-172.
8. Hage CA, Azar MM, Bahr N, Loyd J, Wheat LJ. Histoplasmosis: Up-to-date evidence-based approach to diagnosis and management. *Semin Respir Crit Care Med.* 2015; 36:729-745.

(Received February 24, 2018; Revised May 1, 2018; Accepted May 6, 2018)