

A case of stent thrombosis presenting as acute myocardial infarction related to right coronary artery originating from the left coronary system

Emrah Ermis^{1,*}, Serkan Kahraman², Hakan Ucar¹, Samir Allahverdiyev¹

¹ Department of Cardiology, Biruni University, Faculty of Medicine, Istanbul, Turkey;

² Division of Cardiology, Silivri State Hospital, Istanbul, Turkey.

Summary

Right coronary artery (RCA) originating from the left coronary system is a subtype of single coronary artery (SCA) anomaly, and the origin of RCA as a branch from the left anterior descending artery (LAD) is a very rare variant. A 55-year-old male who had a percutaneous coronary intervention (PCI) history was hospitalized due to acute coronary syndrome. Coronary angiography revealed an aberrant RCA originating from the mid-LAD as well as stent thrombosis. A successful PCI was performed and he was discharged from the hospital three days after the PCI. It is known that there is an increased incidence of atherosclerosis and stent thrombosis in coronary anomaly patients. Therefore, interventional cardiologists should consider the most suitable PCI strategy before stenting and avoid complex techniques.

Keywords: Coronary vessel anomalies, single coronary artery anomaly, percutaneous coronary intervention, stent thrombosis

1. Introduction

The incidence of coronary artery anomaly is about 1.3% in the largest reported series (1). A rare anomaly of the coronary arteries originating from a single coronary ostium in the aorta is called a single coronary artery (SCA) and its incidence ranges from 0.024% to 0.066% in several studies (1,2). Right coronary artery (RCA) originating from the left coronary system is a subtype of this anomaly and the origin of RCA as a branch from the left anterior descending artery (LAD) is a very rare variant of the SCA anomaly. It is known that coronary artery anomalies can be related to coronary ischemia and sudden cardiac death (3).

We herein present a case introducing a patient with a SCA anomaly in which the RCA arose from the LAD mid-segment and percutaneous coronary intervention (PCI) was performed due to stent thrombosis.

2. Case Report

A 67-year-old male having a history of elective PCI two years ago was admitted to our emergency service with chest pain that had been ongoing for three hours. His hemodynamic parameters were stable and he had no property on physical examination. Electrocardiography (ECG) indicated normal sinus rhythm and ST-segment elevation in both the D2-D3-aVF and V1-V3 derivations (Figure 1). At the time he came to the hospital, he had been on clopidogrel for two years because of prior stent implantation. Coronary angiography was performed immediately due to ST-segment elevation acute coronary syndrome (ACS) and following this the LMCA was selectively cannulated with a Judkins Left (JL) 4-6F diagnostic catheter (Medtronic, New York, USA) and the SCA anomaly was demonstrated. It was shown that the RCA arose from the LAD mid-segment and it was seen that the patient had a complex PCI history on the LAD-RCA bifurcation lesion (Figure 2A). There was very late stent thrombosis in the RCA stent, unlike LAD's (Figure 2B). The catheter was changed with a Judkins Left (JL) 4-6F guiding catheter. The LAD and RCA were predilated with 3.0 × 12 mm and 3.0 × 15 mm semi-compliant balloons, respectively (Figure 2C,D). A 3.0 × 23 mm DES (Everolimus eluting coronary stent,

Released online in J-STAGE as advance publication February 26, 2018.

*Address correspondence to:

Dr. Emrah Ermis, Department of Cardiology, Biruni University, Faculty of Medicine, Istanbul, Turkey.

E-mail: emr_ermis@hotmail.com

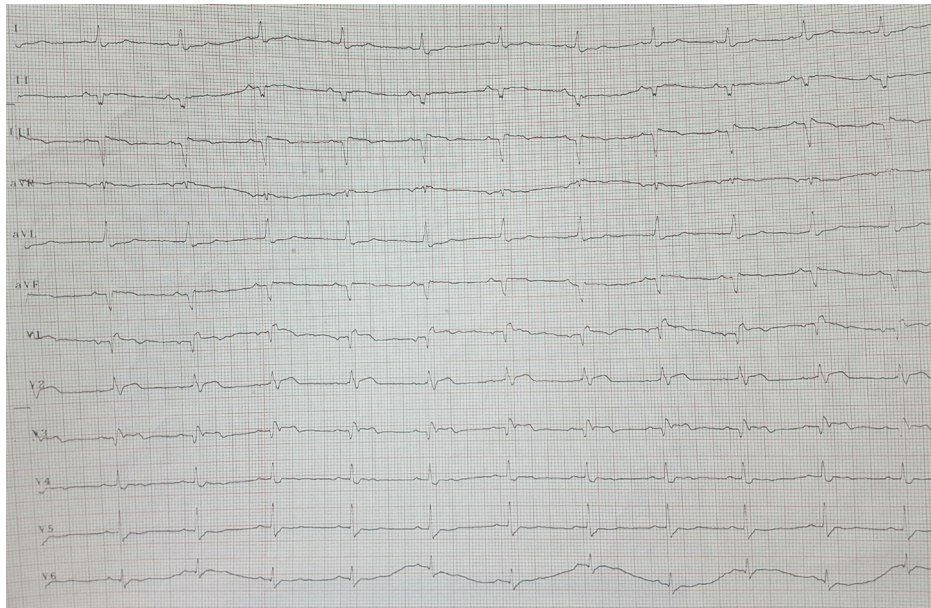


Figure 1. Electrocardiography demonstrates ST-segment elevation.

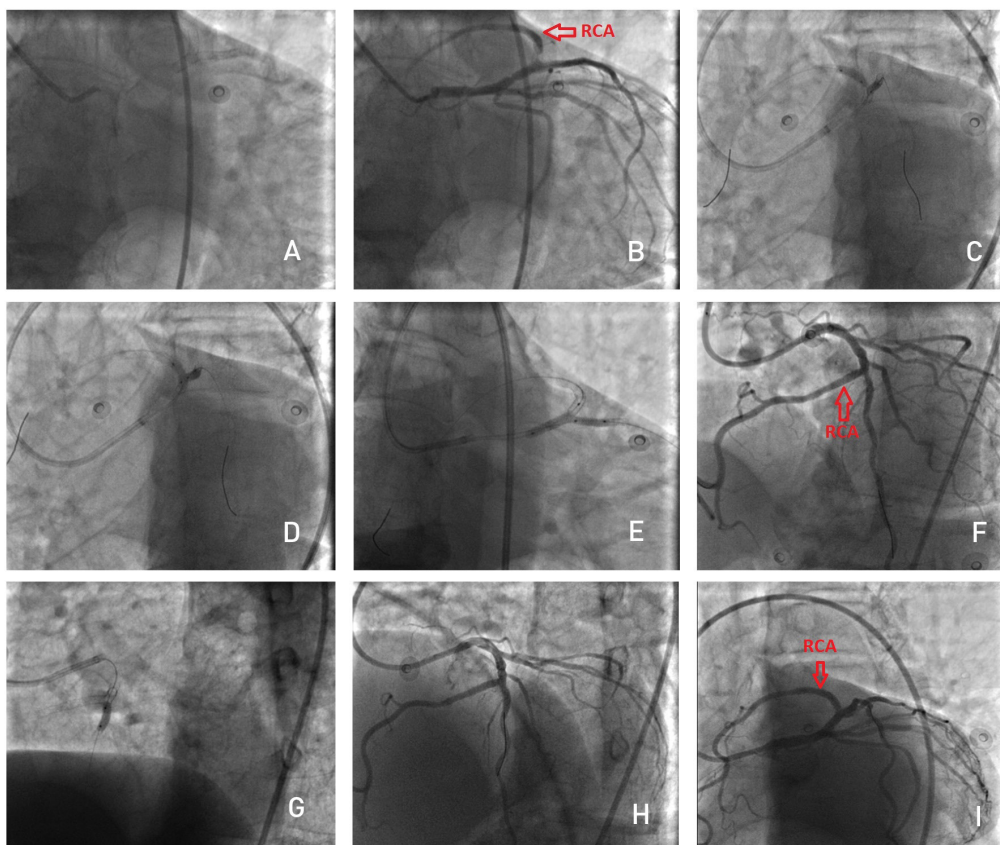


Figure 2. (A) Coronary angiography illustrating the complex coronary intervention on LAD-RCA bifurcation; (B) Appearance of stent thrombosis in RCA stent in caudal position; (C,D) Predilatations before stenting with semi-compliant balloons; (E) Appearance of stent implantation; (F,G) LAD postdilatation with balloon because of a hazy image.

Abbott, CA, USA) was implanted with 18 atm for RCA including pre-stent LAD lesion (Figure 2E). After stent implantation, the procedure was terminated with LAD postdilatation with a 3.5 × 8 mm non-compliant balloon because of a hazy image in LAD after final kissing

(Figure 2F, G). The final angiographic result is illustrated in Figure 2H, I. The patient's hemodynamic parameters were stable after PCI. Antiplatelet treatment changed from clopidogrel to ticagrelor due to ACS on clopidogrel therapy and also 100 mg acetylsalicylic acid treatment

was added to ticagrelor (2 × 90 mg). He was discharged from the hospital three days later after PCI with no symptom relapse.

3. Discussion

The incidence of congenital coronary anomaly is 0.2-1.4% in the normal population (4). Yamanaka and Hobbs reported that the incidence of coronary artery anomaly was 1.3% in their large coronary angiography series with 126,595 patients (1). However, they did not mention SCA anomaly. SCA refers to coronary arteries originating from a single coronary ostium. It was first described by Hyrtl in 1841 (5) and in a larger series its incidence ranged from 0.024% to 0.066% (2). RCA originating from LAD is a very rare variant of SCA. In light of literature analysis, it is an extremely rare anomaly with an incidence of 0.024% in the general population (6). SCA anomaly can be related to other congenital heart diseases, including transposition of the great vessels, coronary arteriovenous fistula, bicuspid aortic valve, tetralogy of Fallot, truncus arteriosus, ventricular septal defect, patent ductus arteriosus and patent foramen ovale (7). None of these properties was seen in our patient.

Although most of SCA anomaly patients are asymptomatic, it is well known that coronary artery anomalies can be associated with chest pain, dyspnea, palpitations, syncope, ventricular fibrillation, myocardial ischemia and sudden cardiac death, especially following exercise. Suggested mechanisms for ischemia include external compression, acute angulation, kinking, torsion, spasm and atherosclerotic obstruction (8). Despite the mechanism of atherosclerosis in SCA patients not being clear, the incidence of atherosclerosis increases in these patients. It is more difficult to perform PCI in SCA anomaly patients than in patients without coronary anomaly. It is known that the incidence of stent restenosis and thrombosis after PCI is higher in these patients than in the normal population (9). This could be the reason for stent thrombosis in our patient who had an anomalous RCA arising from the mid-LAD. Furthermore, the thrombosis occurred in our patient while he was on clopidogrel treatment. Therefore antiplatelet treatment was changed from clopidogrel to ticagrelor, although we were not able to indicate a possible effect of clopidogrel.

Treatment options are medical, percutaneous and surgical for coronary artery anomalies. PCI for RCA arising from LAD was reported by various authors (9,10). However, stent thrombosis rates are higher in these patients than in patients without coronary anomalies. Surgical treatment is used for osteoplasty, bypass grafting of the RCA and translocation of the RCA to the aorta.

4. Conclusion

RCA arising from LAD is a very rare variant of SCA anomaly and can be related to myocardial ischemia.

Abnormal origin or intramural course of the aberrant artery and compression between the main pulmonary artery and the aorta may be the reasons for atherosclerosis in these patients. It is known that performing PCI in SCA anomaly patients is not usually easy. Periprocedural complications and the incidence of stent restenosis and thrombosis are higher in these patients. The main point in the treatment of bifurcation lesions in patients who have coronary anomalies is determination of the most suitable strategy for each lesion. Interventional cardiologists should avoid a complex technique because of the risk of stent thrombosis.

References

1. Yamanaka O, Hobbs RE. Coronary artery anomalies in 126,595 patients undergoing coronary arteriography. *Cathet Cardiovasc Diagn.* 1990; 21:28-40.
2. Desmet W, Vanhaecke J, Vrolix M, Van de Werf F, Piessens J, Willems J, de Geest H. Isolated single coronary artery: A review of 50,000 consecutive coronary angiographies. *Eur Heart J.* 1992; 13:1637-1640.
3. Schwarz ER, Hager PK, Uebis R, Hanrath P, Klues HG. Myocardial ischaemia in a case of a solitary coronary ostium in the right aortic sinus with retroaortic course of the left coronary artery: Documentation of the underlying pathophysiological mechanisms of ischaemia by intracoronary Doppler and pressure measurements. *Heart.* 1998; 80:307-311.
4. Jacobs ML, Mavroudis C. Anomalies of the coronary arteries: Nomenclature and classification. *Cardiol Young.* 2010; 20(suppl 3):15-19.
5. Hyrtl J. Einige in chirurgischer Hinsicht wichtige Gefassvarieteten. *Med Jahrb Osterr Staats.* 1841; 33:17-38.
6. Xuguang Q, Xiang W, Lu C. The coronary anomaly: Right coronary artery originates from the mid left anterior descending artery. *J Invasive Cardiol.* 2010; 22: E166-167.
7. Poynter JA, Williams WG, McIntyre S, Brothers JA, Jacobs ML; Congenital Heart Surgeons Society AAOCA Working Group. Anomalous aortic origin of a coronary artery: A report from the Congenital Heart Surgeons Society Registry. *World J Pediatr Congenit Heart Surg.* 2014; 5:22-30.
8. Nath A, Kennett JD, Politte LL, Sanfelippo JF, Alpert MA. Anomalous right coronary artery arising from the midportion of the left anterior descending coronary artery – Case reports. *Angiology.* 1987; 38:142-146.
9. Rudan D, Todorovic N, Starcevic B, Raquz M, Bergovec M. Percutaneous coronary intervention of an anomalous right coronary artery originating from the left coronary artery. *Wien Klin Wochenschr.* 2010; 122:508-510.
10. Takano M, Seimiya K, Yokoyama S, Okamatsu K, Ishibashi F, Uemura R, Hata N, Mizuno K. Unique single coronary artery with acute myocardial infarction: Observation of the culprit lesion by intravascular ultrasound and coronary angiography. *Jpn Heart J.* 2003; 44:271-276.

(Received January 5, 2018; Accepted February 21, 2018)