

Filarial huge splenomegaly dramatically regressed by anti-filarial medication: A rare clinical scenario

Ayan Basu¹, Arvind Kumar^{1,*}, Smita Manchanda², Naveet Wig¹

¹Department of Internal Medicine, All India Institute of Medical Sciences (AIIMS), New Delhi, India;

²Department of Radio diagnosis, All India Institute of Medical Sciences (AIIMS), New Delhi, India.

Summary

Lymphatic filariasis is caused by nematodes *Wuchereria bancrofti*, *Brugia malayi* and *Brugia timori*. Lymphatic filariasis is a spectrum of illness and can manifest as, asymptomatic microfilariemia, acute lymphatic filariasis (lymphangitis and lymphoedema), chronic lymphoedema, elephantiasis, hydrocele, tropical pulmonary eosinophilia and some systemic manifestations which involves joint, heart, kidney, nerve, etc. We here present a case of huge splenomegaly caused by lymphatic filariasis which is a rare presentation and only few cases had been reported in the world literature so far. After treatment of filariasis spleen size was reduced dramatically and patient is doing well even after 6 months of follow up after therapy.

Keywords: Filariasis, lymphatic, splenomegaly

1. Introduction

Lymphatic filariasis is one of the oldest & neglected tropical disease. Nearly 1.4 billion people worldwide are threatened by lymphatic filariasis and over 120 million people are currently infected. After leprosy, lymphatic filariasis is the second most common cause of long term disability (1). India, China & Indonesia jointly bear the burden of 2/3rd of all caseloads (2). In India lymphatic filariasis is endemic in seventeen states & six union territories affecting almost thirty one million people (3). It is endemic in Orissa, where its prevalence is very high in the coastal district of Cuttack. Although a common disease, there are very few reports in the world literature indicating possible involvement of the spleen in lymphatic filariasis. However, there are several case reports of incidental detection of microfilariae in the bone marrow without any other clinical findings of lymphatic filariasis (4-11).

2. Case Report

62 years old non-alcoholic, non-smoker male patient

resident of east Champaran district of Bihar presented to our outpatient department with slowly progressive massive splenomegaly and easy fatigability for 8 months. He had a past history of peripheral blood eosinophilia (25%) for which he was given tablet Di Ethyl Carbamazine Citrate (DEC) for inadequate dose and duration (100 mg tid for 7 days) by a local physician with some reduction of eosinophilia but without any reduction of size of spleen. He had past history of occasional intermittent fever for few days 6 months ago but without any weight loss, jaundice, ascites, haematemesis, melaena, cough, wheeze, haemoptysis, lymphangitis, lymphadenopathy or hydrocele. He had no past history of tuberculosis, recurrent malaria, diabetes or blood transfusion. On examination only mild pallor and 14 cm firm splenomegaly were found without any hepatomegaly, lymphadenopathy or bony tenderness. Other systemic examinations were unremarkable. Investigations showed pancytopenia with Haemoglobin (Hb) 9.4 gm/dL, Total Leucocyte Count (TLC) 3000/cmm (Differential leucocyte count ie DLC showed-Neutrophil-59%, Lymphocyte-22%, Eosinophil-10.4%, Monocyte-8%, Basophil-0.6%), platelet count 88000/cmm, haematocrit 28.5%, Mean Corpuscular Volume (MCV) 83.7, Mean Corpuscular Haemoglobin (MCH) 26.8, Mean Corpuscular Haemoglobin Concentration (MCHC) 32, reticulocyte count 0.8%, Direct Coombs test was negative. Liver

*Address correspondence to:

Dr. Arvind Kumar, 4097, Teaching Block, All India Institute of Medical Sciences, New Delhi 110029, India.

E-mail: linktoarvind@gmail.com

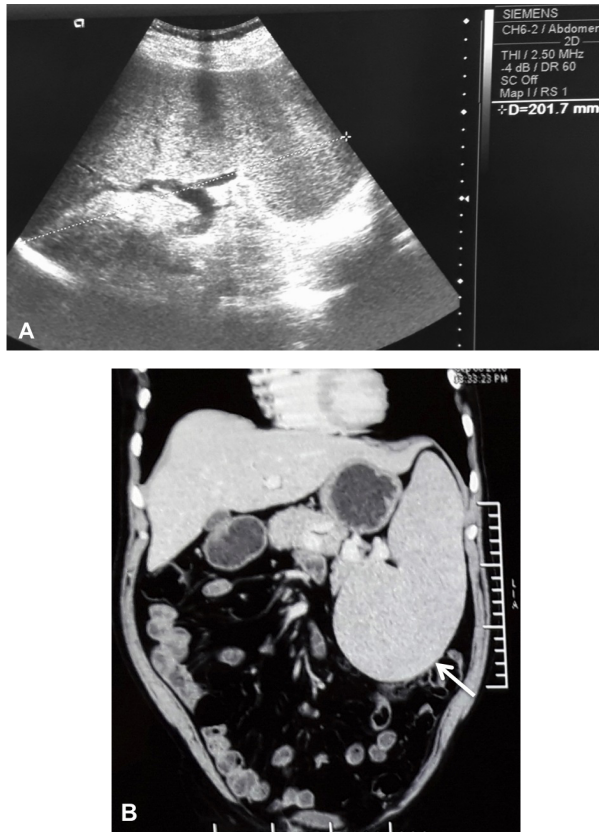


Figure 1. (A) Baseline ultrasound reveals gross splenomegaly (size 20.1 cm) and (B) CECT coronal reformatted image reveals the markedly enlarged (22 cm), homogenous spleen (arrow).

function test showed total bilirubin 0.7 mg/dL with unconjugated bilirubin 0.4, total protein 6.6gm% and albumin 4.7gm%, AST (Aspartate Aminotransferase) 21 IU/L, ALT (Alanine Aminotransferase) 11 IU/L and alkaline phosphatase 213 IU/mL, Prothrombin time 13.6 sec and INR 1.2, urea 36 and creatinine was 1.2 mg/dL, fasting blood sugar 96 mg/dL, vitamin B12 403 ng/mL, folate 6.24 ng/mL, ferritin 77.5 μ gm/mL, LDH 383, thyroid and lipid profile were normal. rK 39 strip test and anti-malarial antibody tests were negative. HBsAg (Hepatitis B surface antigen), anti HCV (Hepatitis C Virus) antibody and HIV serology were non-reactive. Examination of stool did not reveal any ova parasite or cyst. Ultrasonography (USG) and computed tomography of abdomen showed huge splenomegaly (20 cm and 22 cm respectively) (Figure 1A and 1B) without any evidence of portal hypertension, ascites, hepatomegaly or intra-abdominal lymphadenopathy. Chest X ray and upper gastro intestinal endoscopy were normal. Immunohistochemistry study showed normal banding. 18F FDG (Fluoro Deoxy Glucose) whole body Positron Emitted Tomography Computed Tomography (PET CT) study revealed metabolically active mediastinal lymph nodes (largest being 2.1 \times 1.5 cm) with fibrotic changes in the right lung apex but FNAC (Fine Needle Aspiration Cytology) could not

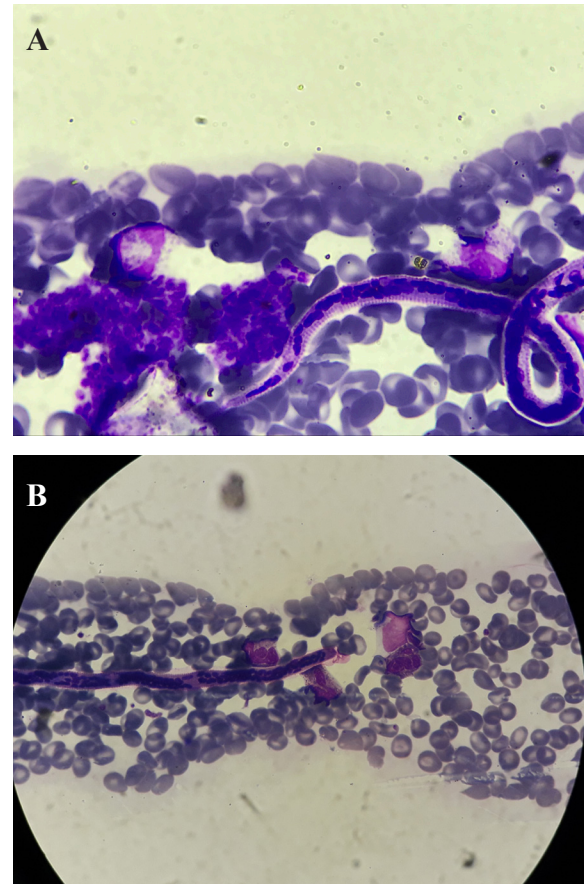


Figure 2. Microscopic finding. (A & B) Microfilariae of *Wuchereria bancrofti* in bone marrow.

be done due to the location of lymph node near blood vessels. Bone marrow aspirate showed cellular reactive bone marrow with all haematopoietic cells and adequate megakaryocytes. Myeloid cells showed prominence of eosinophils. Erythroid cells showed normoblastic maturation. Few histiocytes were seen. Peripheral smear showed normal total leucocyte count and adequate platelets with 60% neutrophils. No atypical cells were seen. There was occasional microfilariae of *Wuchereria bancrofti* seen (Figure 2A and 2B). Biopsy report showed adequate bone marrow with normal marrow cellularity and normal marrow components. Occasional well defined small mature lymphoid cell aggregates were seen.

Suspecting it was a case of extra lymphatic manifestation of filariasis we performed circulating filarial antigen test and it became positive. Though quantitative buffy coat test even after single 100 mg of tab DEC challenge did not reveal any microfilariae or malaria parasite. So we started tablet DEC at a dose of 150 mg thrice daily (6 mg/kg/day, patient's body weight was 71 kg) and tablet doxycycline 100 mg twice daily for a total duration of 21 days. Five days after therapy his spleen size was regressed to 9 cm per abdominal palpation and 16.2 cm on ultrasonography (Figure 3A). Ten days after therapy his spleen size reduced to

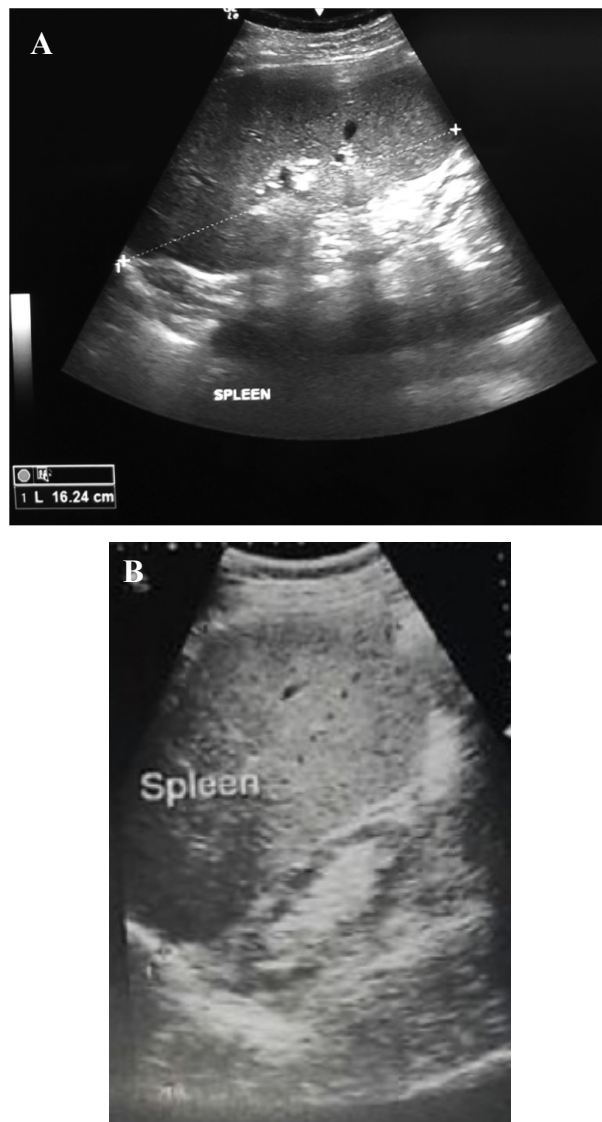


Figure 3. Ultrasonography done at 5th day (A) and end of the treatment (B) showed reduction of splenomegaly (16.24 cm and 12.5 cm respectively).

4 cm per abdominal palpation (USG- 15.3 cm) and his complete blood count improved (Hb 12.3, TLC 4200, N 61, L 28, E 6, M 4, B 1, platelet count 90,000). After completion of treatment patient was advised to take monthly single dose of 300 mg tablets of DEC and single 400 mg tablet of Albendazole for 6 months and then yearly thereafter for 5 years. Patient is symptomatically well with improvement of blood parameters and total regression of splenomegaly (Figure 3B) after 6 months of follow up (see Table 1 and Table 2).

3. Discussion

Wuchereria bancrofti, *Brugia malayi*, or *B. timori* affect the lymphatic vessels structure and function as well as some extralymphatic organs. Diagnosing extralymphatic filariasis poses a real challenge as symptoms and signs mimic other non-filarial diseases. There were several case reports of incidental detection of microfilariae in the bone marrow. In 1976, Pradhan *et al.* reported the first case of microfilariae in bone marrow aspirate (4). They showed *W. bancrofti* in peripheral blood and bone marrow in 7 cases but none had aplastic anaemia. However many authors have reported the coexistence of aplastic anaemia and microfilariae of *W. bancrofti* (5-7). Microfilariae of *W. bancrofti* have been isolated from various cytological smears, like fine needle aspiration cytology, body fluids, vaginal and endometrial smears, ovarian cyst, laryngeal, pharyngeal and bronchial brushings, breast and joint aspirates (12,13). In the lymphatic system and lymph node adult parasite of *W. bancrofti* settles down and produce microfilariae which enters circulation through thoracic duct and gets lodged in various organs like lungs, liver, spleen, lymph nodes, and bone marrow. Uzma Zafar *et al.* (8) reported an interesting case of low back pain and destruction of first lumbar vertebra by the microfilariae residing in the

Table 1. Improvements of haematological parameters after start of therapy

Investigations	At presentation	10 days after treatment	At the end of treatment	1 month after end of treatment
Hb (gm/dL)	9.4	12.3	12.8	13
TLC (per cmm)	3,000	4,200	4,700	5,100
DLC(N,L,E,M,B)	N-59, L-22, E-10.4, M-8, B-0.6	N-61, L-28, E-6, M-4, B-1	N-61, L-34, E-3, M-2, B-0	N-60, L-32, E-3, M-4, B-1
Haematocrit (%)	28.5	37.8	36.8	36.2
Platelet (per cmm)	88,000	90,000	98,000	120,000

Table 2. Regression of size of spleen after treatment

Spleen size	At presentation	5 days after treatment	10 days after treatment	At the end of treatment	1 month after end of treatment
Per abdominal palpation (in cm from left costal margin)	14	9	4	Just palpable	Not palpable
Ultrasonography (in cm)	22	16.24	15.3	12.5	11.6

bone marrow. There were several case reports of huge splenomegaly in leukaemia patients with incidental detection of bone marrow microfilariae (9-11). Possible explanation for splenomegaly in those cases were due to leukaemia not filariasis because spleen is usually not involved in filariasis except in some experimentally infected animals although Schuurkamp GJ *et al.* (14) showed occurrence of filarial splenomegaly in their articles.

But our case was unique because here splenomegaly was solely due to filariasis. It was further proved by regression of size of the spleen by antifilarial medications. A study conducted by Schuurkamp GJ *et al.* showed that splenomegaly in the Ok Tedi region of Papua New Guinea was solely due to Bancroftian filariasis, and splenomegaly due to filariasis could be controlled or even reduced by mass drug administration of DEC. This was observed in the 5 villages participating in the initial program. A significant reduction in splenomegaly by DEC was reported in another 7 villages in the expanded program during Phase 2; Enlarged spleen rates were reduced from 50% (1986) to 32% (1990) and from 76% (1988) to 48% (1990), respectively (14).

In conclusion, patients presenting from filaria endemic area with splenomegaly and with either symptoms or initial investigations suggestive, filaria should be given a serious thought with other well-known causes of splenomegaly. Because a simple regimen of DEC can make patient get rid of cumbersome splenomegaly, which is not commonly mentioned or known in the world literature.

References

1. World Health Organization. Global programme to eliminate lymphatic filariasis: Progress report. *Wkly Epidemiol Rec.* 2015; 90:489-504. <http://www.who.int/wer/2015/wer9038.pdf> (accessed on July 22, 2017).
2. Williams NS, O'Connell PR, Hodder Arnold. Filariasis. In: *Bailey & Love's Short Practice of Surgery.* CRC Press, UK, 2013; pp 73.
3. Suma TK. Indian scenario of elimination of lymphatic filariasis. In: *Medicine update, Association of Physicians of India.* Munjal YP, Kolkata, India, 2013; pp. 6-9. http://www.apiindia.org/content_mu_2013.html (accessed on July 22, 2017).
4. Pradhan S, Lahiri VL, Ethence BR, Singh KN. Microfilariae of *Wuchereria bancrofti* in bone marrow smear. *Am J Trop Med Hyg.* 1976; 25:199-200.
5. Hemachandran M, Varma N, Varma S. Aplastic anemia following Varicella infection with coexistent microfilarimiasis of *Wuchereria bancrofti* – A case report. *Indian J Pathol Microbiol.* 2003; 46:662-663.
6. Sheno U, Pai RR, Usha P, Nanadi GK, Adhikari P. Microfilariae in bone marrow aspiration smears. *Acta Cytol.* 1998; 42:815-816.
7. Sharma S, Rawat A, Chouhan A. Microfilariae in bone marrow aspiration smear, correlation with marrow hypoplasia: A report in six cases. *Indian J Pathol Microbiol.* 2006; 49:556-558.
8. Zafar U, Rahman K, Sherwani RK, Shahid M. Microfilariae of *Wuchereria bancrofti* in bone marrow. *Indian J Hematol Blood Transfus.* 2009; 25:42-43.
9. Arundhati, Kumar A, Kumar R. Acute lymphoblastic leukaemia with microfilaria: A rare coincidence in bone marrow aspirate. *Indian J Hematol Blood Transfus.* 2011; 27:111-112.
10. Rahman K, George S, Sardana M, Mehta A. Microfilariae with acute myeloid leukaemia: A common parasite with uncommon association. *Indian J Hematol Blood Transfus.* 2013; 29:113-115.
11. Pahwa S, Saksena A, Singh A, Daga MK, Singh T. Blastoid phase of CML with microfilaria: A rare case report. *J Clin Diagn Res.* 2015; 9:ED09-ED10.
12. Anupindi L, Sahoo R, Rao RV, Verghese G, Rao PV. Microfilariae in bronchial brushing cytology of symptomatic pulmonary lesion: A report of two cases. *Acta Cytol.* 1993; 37:397-399.
13. Verghese R, Raghuvver CV, Pai MR, Bansal R. Microfilariae in cytologic smear: A case report of six cases. *Acta Cytol.* 1996; 40:299-301.
14. Schuurkamp GJ, Kereu RK, Bulungol PK, Kawereng A, Spicer PE. Diethylcarbamazine in the control of bancroftian filariasis in the Ok Tedi area of Papua New Guinea: Phase 2 annual single dose treatment. *P N G Med J.* 1994; 37:65-81.

(Received July 19, 2017; Revised August 25, 2017; Accepted August 26, 2017)