

Gomez-Lopez-Hernández syndrome: First reported case from the Indian subcontinent

Anita Choudhary, Priyanka Minocha*, Sadasivan Sitaraman

Department of Pediatrics, SMS Medical College and Hospital, Jaipur, Rajasthan, India.

Summary

Gomez-Lopez-Hernández syndrome (GLHS) is a rare neurocutaneous syndrome characterized by a triad of findings: partial alopecia of the scalp, trigeminal anaesthesia, and rhombencephalosynapsis. GLHS is also known as cerebello-trigeminal-dermal dysplasia. Besides this triad, a number of varying traits have been described in 35 previously reported cases. Reported here is a case of a four-year-old boy, born out of consanguineous marriage, presenting with the classic triad of findings, *i.e.* partial alopecia of the scalp, trigeminal anaesthesia, and rhombencephalosynapsis. To the extent known, this is the first case of GLHS reported from India. If a child presents with alopecia and rhombencephalosynapsis, GLHS should be considered in the differential diagnosis. A host of studies can be used to determine the exact pathogenesis, and confirming the diagnosis of GLHS is an important step in prenatal testing for at-risk pregnancies.

Keywords: Alopecia, rhombencephalosynapsis, trigeminal anaesthesia, autosomal recessive

1. Introduction

Gomez-Lopez-Hernández syndrome (GLHS) (OMIM 601853) is a rare neurocutaneous syndrome that is characterized by triad of findings: partial alopecia of the scalp, trigeminal anaesthesia, and rhombencephalosynapsis. Thus far, only 35 cases had been described with varying symptomatology (1,2). Genetic factors responsible for GLHS are poorly understood. Recently, possibility of autosomal recessive transmission was suggested by Vinicius *et al.* in view of reported consanguinity in parents of some reported cases (2).

GLHS was first described by Manuel Gomez in 1979 in a girl. He postulated that the patient had a cerebellotrigeminal and focal dermal dysplasia due to a developmental arrest of the ectoderm, which gives rise to the alar plate of the rhombencephalon, the overlying epidermis, the motor nucleus of V, and the trigeminal placodes (3). In 1982, Lopez Hernández described a new neurocutaneous syndrome in two Mexican girls with

a similar presentation in which a cerebellar anomaly (ponsvermis fusion anomaly with atresia of the fourth ventricle) was confirmed by a CT scan (4). Rush *et al.* and Sukhudyen *et al.* attempted to describe the diagnostic criteria for GLHS since the triad of findings are not found in all patients (1,5).

Reported here is the case of a child with the classic triad of findings, *i.e.* partial alopecia of the scalp, trigeminal anaesthesia, and rhombencephalosynapsis. This child was the product of a third-degree consanguineous marriage, making autosomal recessive transmission a likely cause. To the extent known, this is the first case of GLHS reported from India.

2. Case Report

A 4-year-old boy who was second in birth order and born from a third-degree consanguineous marriage and who had an uneventful antenatal and perinatal history presented with developmental delay, abnormal head movements, and seizures since 2 years of age. There was no family history of similar features. On clinical examination, the boy's body measurements were as follows: weight 10 kg (≤ 3 SD), height 94 cm (≤ 2 SD), and head circumference (HC) 48 cm. His characteristic craniofacial features (Figure 1, Table 1) included a flat occiput, brachyuricephaly, low-set ears, a patch of alopecia (Figure 2) present above both ears, thin

Released online in J-STAGE as advance publication December 21, 2016.

*Address correspondence to:

Dr. Priyanka Minocha, Department of Pediatrics, SMS Medical College and Hospital, Jaipur, Rajasthan 302004, India.
E-mail: dr.priyankaminocha@gmail.com

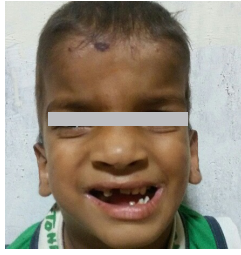

Figure 1. Craniofacial features showing brachyturricephaly, low-set ears, thin lips, and hypertelorism.

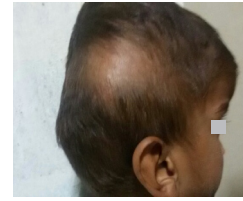

Figure 2. A patch of alopecia present above both ears.

Table 1. Comparison of traits in previously described cases and the current case

Trait	Previously reported cases	Current case
<i>Craniofacial</i>		
Alopecia of the scalp	35/35	+
Low-set ears	30/33	+
Brachycephaly and/or turricephaly	29/34	+
Mid-face retrusion	27/33	+
Strabismus	22/29	-
Trigeminal anesthesia	18/32	+
Absent corneal reflexes	18/31	+
Widely spaced eyes	21/31	+
Interstitial keratitis or corneal clouding	14/32	-
Lambdoid craniosynostosis	10/21	-
Plagiocephaly	14/20	-
<i>Neurodevelopmental</i>		
Delayed motor milestones	27/28	+
Ataxia	19/26	-
Hypotonia	20/27	-
Intellectual disability	21/30	+
Head shaking or other stereotypical behavior	15/19	+
<i>Radiologic</i>		
Rhombencephalosynapsis	34/34	+
Ventriculomegaly/hydrocephalus	21/31	-
Cerebellar hypoplasia	12/31	+
<i>Other</i>		
Hypoplastic labia majora	5/9	NA
Normal growth at birth	18/23	+
Short stature	17/26	+

lips, and hypertelorism. Informed written consent was obtained from the parents of the child.

The child had stereotypical head shaking (yes-yes). Anesthesia was present along the path of the trigeminal nerve and corneal opacity was present in the left eye. He had moderate intellectual disability (IQ 58). Karyotyping, abdominal ultrasonography, an X-ray of the spine, two-dimensional echocardiography, and fundoscopy were normal. MRI of the brain (Figure 3) revealed rhombencephalosynapsis (absent cerebellar vermis with apparent fusion of cerebellar hemispheres) and cerebellar hypoplasia. EEG showed generalized epileptiform discharges.

3. Discussion

GLHS is a rare neurocutaneous syndrome. In previously described cases, the most consistent findings were scalp alopecia and rhombencephalosynapsis while

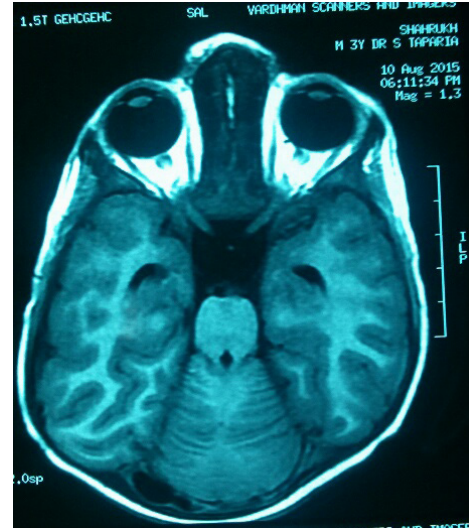


Figure 3. MRI of the brain revealed rhombencephalosynapsis i.e. absent cerebellar vermis with apparent fusion of the cerebellar hemispheres.

the third finding of the classical triad, i.e. trigeminal anaesthesia, was present in only 56% of cases. Other craniofacial features of this syndrome are low-set ears, brachyturricephaly, mid-face retrusion, widely spaced eyes, strabismus, craniosynostosis, and plagiocephaly. Based on these findings, Rush *et al.* (1) described criteria for defining definitive, probable, and possible GLHS. The current case qualifies as definitive GLHS since all of the classic findings were present.

Ataxia, hypotonia, stereotypical head movements, and intellectual disability are some important neurological features described in GLHS. Stereotypical head movements are typically described as side-to-side "no" movements, up-and-down "yes" movements, or shoulder-to-shoulder movements (6,7). The child in the current case displayed repeated up and down "yes" movements of the head. These stereotypical movements are characteristic of GLHS and provide a clue to the diagnosis of rhombencephalosynapsis and GLHS.

Rhombencephalosynapsis is defined as midline brain malformation characterized by absent cerebellar vermis with apparent fusion of the cerebellar hemispheres. It is usually noted in GLHS along with characteristic findings of alopecia and trigeminal anaesthesia, but it can also occur as isolated entity. Rhombencephalosynapsis is also seen in patients with the VACTERL association, i.e. vertebral anomalies, anal atresia, cardiovascular anomalies, tracheaesophageal fistula, renal anomalies,

and limb defects. More than 90 individuals with rhombencephalosynapsis have been reported in the literature, and 25 of those individuals were found to have GLHS (8). This indicates that rhombencephalosynapsis is a consistent finding in GLHS. Other neuroimaging findings noted in GLHS are ventriculomegaly/hydrocephalus and cerebellar hypoplasia.

Consanguinity has been described in only 2 previously reported cases (2,9) and the child in the current case is the third such case involving parents with a history of consanguineous marriage, making autosomal recessive transmission a likely cause. That said, further studies and whole-genome sequencing need to be performed to pinpoint the exact pathogenesis.

In conclusion, GLHS is rare neurocutaneous syndrome with unknown genetic causes. High degree of suspicion in a child presenting with characteristic alopecia and rhombencephalosynapsis has a great importance in diagnosis of GLHS. A host of studies can be used to determine the exact pathogenesis, and confirming the diagnosis of GLHS is an important step in prenatal testing for at-risk pregnancies

References

1. Rush ET, Adam MP, Clark RD, Curry C, Hartmann JE, Dobyns WB, Olney AH. Four new patients with Gomez-Lopez-Hernandez syndrome and proposed diagnostic criteria. *Am J Med Genet.* 2013; 161A:320-326.
2. de Mattos VF, Graziadio C, Machado Rosa RF, Lenhardt R, Alves RP, Trevisan P, Paskulin GA, Zen PR. Gómez-López-Hernández syndrome in a child born to consanguineous parents: New evidence for an autosomal-recessive pattern of inheritance? *Pediatr Neurol.* 2014; 50:612-615.
3. Gomez MR. Cerebellotrigeminal and focal dermal dysplasia: A newly recognized neurocutaneous syndrome. *Brain Dev.* 1979; 1:253-256.
4. Lopez-Hernandez A. Craniosynostosis, ataxia, trigeminal anaesthesia and parietal alopecia with ponsvermis fusion anomaly (atresia of the fourth ventricle). Report of two cases. *Neuropediatrics.* 1982; 13:99-102.
5. Sukhudyay B, Jaladyan V, Melikyan G, Schlump JU, Boltshauser E, Poretti A. Gomez-Lopez-Hernandez syndrome: Reappraisal of the diagnostic criteria. *Eur J Pediatr.* 2010; 169:1523-1528.
6. Bonnet C, Roubertie A, Doummar D, Bahi-Buisson N, Cochen de Cock V, Roze E. Developmental and benign movement disorders in childhood. *Mov Disord.* 2010; 25:1317-1334.
7. Harris KM, Mahone EM, Singer HS. Nonautistic motor stereotypies: Clinical features and longitudinal follow-up. *Pediatr Neurol.* 2008; 38:267-272.
8. Ishak GE, Dempsey JC, Shaw DW, Tully H, Adam MP, Sanchez-Lara PA, Glass I, Rue TC, Millen KJ, Dobyns WB, Doherty D. Rhombencephalosynapsis: A hindbrain malformation associated with incomplete separation of midbrain and forebrain, hydrocephalus and a broad spectrum of severity. *Brain.* 2012; 135:1370-1386.
9. Gomy I, Heck B, Santos AC, Figueiredo MS, Martinelli CE Jr, Nogueira MP, Pina-Neto JM. Two new Brazilian patients with Gómez-López-Hernández syndrome: Reviewing the expanded phenotype with molecular insights. *Am J Med Genet A.* 2008; 146A:649-657.

(Received September 21, 2016; Revised November 10, 2016; Accepted November 16, 2016)