

Disseminated mucormycosis: A sinister cause of neutropenic fever syndrome

Ghazal Tansir¹, Neha Rastogi², Prashant Ramteke³, Prabhat Kumar^{1,*}, Manish Soneja¹, Ashutosh Biswas¹, Sanchit Kumar¹, Pankaj Jorwal¹, Upendra Baitha¹

¹Department of Medicine, All India Institute of Medical Science, New Delhi, India;

²Division of Infectious Disease, Department of Medicine and Microbiology, All India Institute of Medical Science, New Delhi, India;

³Department of Pathology, All India Institute of Medical Science, New Delhi, India.

Summary

A 15 year old girl presented with complaints of prolonged fever and recurrent episodes of hemoptysis. Initial investigation showed pancytopenia and radiological imaging was suggestive of necrotizing pneumonia. Subsequently, mucor was isolated from bronchoalveolar lavage fluid, but even on appropriate medications her condition kept deteriorating. She had multiple bouts of hemoptysis and a repeat imaging of chest showed dissemination of mucormycosis to pulmonary vein and heart. Bone marrow biopsy identified acute lymphoblastic leukemia (ALL) as the cause of pancytopenia. She was planned for bronchial artery embolization and chemotherapy for ALL, but consent was not given and she left our institute against medical advice. Our case highlights the importance of keeping a high index of suspicion for disseminated mucormycosis in neutropenic patients, as any delay in diagnosis and treatment could have grave consequences.

Keywords: Cardiac mucormycosis, acute lymphoblastic leukemia, galactomannan

1. Introduction

Fever in neutropenic patient is a medical emergency and warrants extensive evaluation and appropriate management. The risk of infection increases with severity and duration of neutropenia (1). Bacterial infections are the most common cause of neutropenic fever. Fungal infection often complicates these individuals and can have myriad presentations. Most of these invasive fungal infections are caused by *Candida* and *Aspergillus* spp. Mucormycosis is a rare infection in neutropenic patients and carries a grave prognosis (2).

Mucorales are responsible for life threatening mucormycosis infection in the immunocompromised. Increasing incidence of this infection has recently been observed in the immunocompromised population. This includes patients with uncontrolled diabetes

especially in ketoacidosis, on prolonged steroid or broad spectrum antibiotic therapy, on voriconazole prophylaxis, hematological malignancies, hematopoietic stem cell transplants, burns and penetrating trauma. The aggressive, angio-invasive nature of the disease, coupled with weakened host defenses is responsible for its devastating consequences (3). There has been an increase in the incidence of mucormycosis in recent times, yet it still largely remains under-diagnosed. Disseminated mucormycosis is the least common type and mostly begins in lung and then disseminates to other sites. Dissemination of pulmonary mucormycosis to heart is unusual and diagnosis is often made on autopsy, antemortem diagnosis of this entity is very rare and only three such cases have been reported so far (4-6). We present a rare case of disseminated mucormycosis having pulmonary and cardiac involvement in a young girl with previously undiagnosed hematological malignancy.

2. Case Report

A 15 year old girl presented in medical emergency of our institute on 26th July 2017, with a five month history of continuous, low grade fever with early satiety and easy fatigability, productive cough for one month which

Released online in J-STAGE as advance publication November 14, 2017.

*Address correspondence to:

Dr. Prabhat Kumar, Department of Medicine, 3rd floor, Teaching Block, All India Institute of Medical Science, New Delhi 110029, India.

E-mail: drkumar.prabhat@gmail.com

was associated with recurrent episodes of epistaxis and hemoptysis. She was treated at a local hospital and found to have pancytopenia and pneumonia. She was managed with blood transfusions along with antibiotics and referred to our institute for further management.

On examination, she had tachycardia and tachypnea, with pallor and significant submandibular lymphadenopathy. There was bronchial breath sounds with crepitations over the left infrascapular and infraaxillary regions of the chest. Preliminary

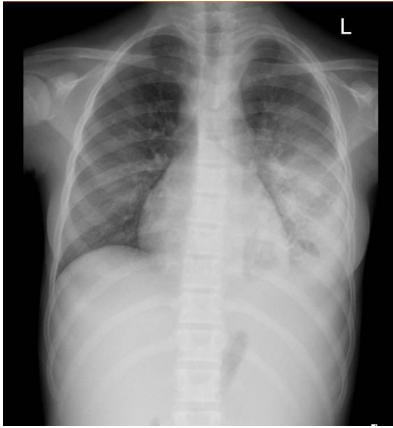


Figure 1. Chest X ray showing left middle and lower zone opacity with blunted left costophrenic angle.

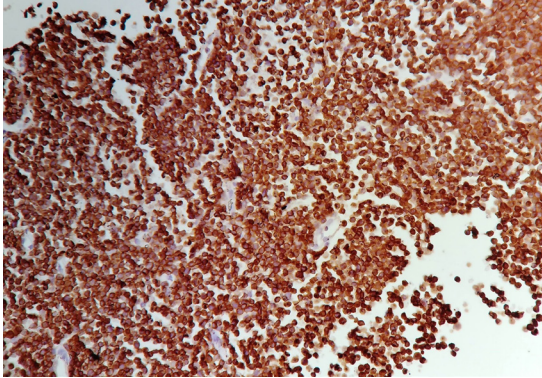


Figure 2. Immunohistochemistry slide (10x) with CD20 positive sheets of immature B-lymphocytes.

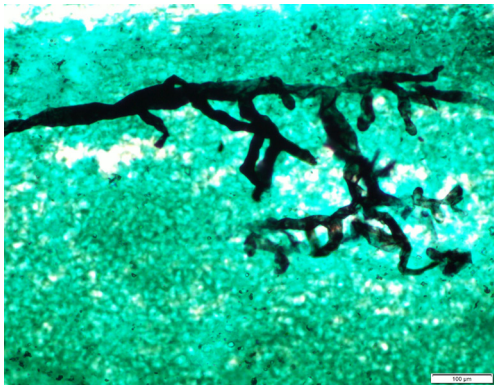


Figure 3. Silver methenamine staining (40x) showing aseptate broad fungal hyphae with wide angle branching suggestive of mucormycosis.

investigations revealed pancytopenia with hemoglobin - 5.6 gm/dL, total leucocyte count (TLC) - 1,400/cu mm, platelets - 45,000/cu mm and an absolute neutrophil count of 980/cu mm. Her peripheral smear was suggestive of pancytopenia with normocytic normochromic anemia. Serum Vitamin B12, folate and Lactate Dehydrogenase (LDH) levels were normal.

Chest X Ray showed heterogeneous opacity over left middle and lower zone with blunting of left costophrenic angle (Figure 1). A Contrast Enhanced Computed Tomography (CECT) of chest revealed necrotizing pneumonia with organized empyema in the left lung. 2D Echocardiography was suggestive of mild pericardial effusion and all cardiac chambers were normal. Her blood, urine and sputum cultures were sterile. Sputum examination didn't show any acid fast bacilli and cartridge based nucleic acid amplification test (GeneXpert) for mycobacterium tuberculosis (MTB) was negative. Serum procalcitonin level was normal and serum galactomannan was not detected. The patient was empirically started on intravenous antibiotics (piperacillin-tazobactam with teicoplanin) and liposomal Amphotericin B (5 mg/kg/day).

Gradually she responded to treatment with improvement in fever and hematological profile. On day 6, her hemoglobin was 8.1 gm/dL, TLC was 2,000/cu

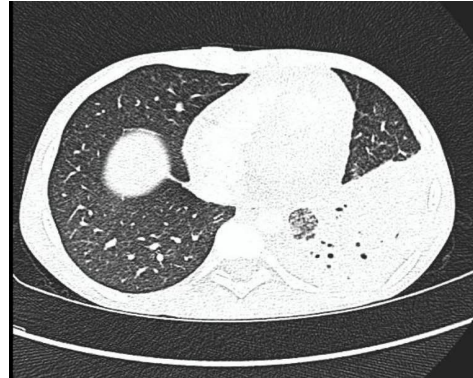


Figure 4. CECT Chest showing left lung necrotizing pneumonia.

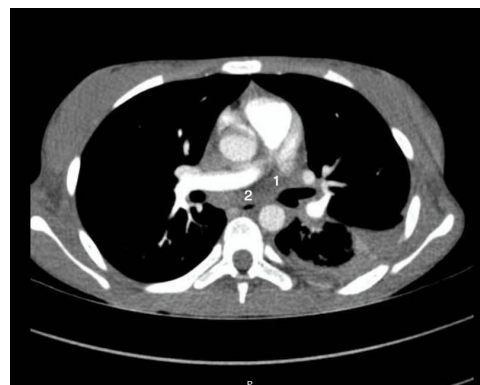

Figure 5. CECT Chest with absence of contrast filling in left pulmonary vein (1) and left atrium (2) suggestive of thrombosis.

mm and platelet count was 63,000/cu mm. Review chest ultrasound revealed an organized empyema with non-drainable contents. Hence, a bronchoalveolar lavage (BAL) was performed. Bone marrow aspiration and biopsy were also performed. While we waited the BAL and bone marrow reports, her blood flow cytometry suggested presence of atypical lymphoid cells. Subsequently, her bone marrow biopsy revealed the presence of sheets of immature cells immunopositive for CD20 and terminal deoxynucleotidyl transferase (TdT) clinching the diagnosis of B-cell Acute Lymphoblastic Leukemia (Figure 2). BAL showed acute inflammatory exudate with aseptate broad fungal hyphae with wide angle branching consistent with mucormycosis (Figure 3). BAL was negative for acid-fast bacilli, GeneXpert MTB and galactomannan.

By day 15, the patient began to run fever again and experienced multiple episodes of hemoptysis. So, a repeat CECT chest was carried out urgently. This time, there was a large necrotizing pneumonia in the left lung along with intraluminal extension of the mass into the left pulmonary vein until the left atrium. The inferior pulmonary vein was also encased by the mass (Figure 4 and Figure 5). 2D Echocardiography showed a left atrial thrombus of (9 × 7 mm) entering through the left inferior pulmonary vein, suggestive of intracardiac mucormycosis. Addition of caspofungin for combination therapy and surgical intervention was planned for the patient. However her family did not consent for further treatment and left our hospital against medical advice on 13th August 2017.

3. Discussion

Mucormycosis is an uncommon, life-threatening infection caused by ubiquitous fungi of the group Mucorales. The vast spectrum of mucormycosis depends on the underlying condition. The infection can be of rhino-orbito-cerebral, pulmonary, gastrointestinal, cutaneous, renal and disseminated types. Mucormycosis is said to be disseminated when it involves two or more noncontiguous sites. Overall, rhino-orbito-cerebral involvement is most common (48%) with diabetics predominantly harboring the condition (7). Pulmonary mucormycosis is found in 17% of cases, most commonly in patients with hematological diseases. Disseminated disease forms the least common type (5%) and mostly begins with pulmonary mucormycosis (8). The most common site of dissemination is cerebral with involvement also being reported in spleen, heart, kidney and other organs. The vasculotropic nature of the infection leads to angioinvasion and widespread tissue necrosis contributing to the fatality of disease. Indeed, pulmonary mucormycosis has a mortality of 76% that increases to more than 90% with dissemination (9).

Patients of hematological disorders are especially susceptible to mucormycosis due to effects of

chemotherapeutic drugs and the underlying cytopenias. Acute leukemia is the most common hematological disorder (78%), followed by lymphomas, myelodysplastic syndrome, multiple myeloma and aplastic anemia (10). Studies have found mucormycosis to be the third most common fungal infection in hematological malignancies after *Aspergillus* and *Candida*, with a share of 13% (11). And though the prevalence of mucormycosis in hematological malignancies is reported as 4.29 per 100 patients, it is probably an underestimation because this disease remains under-diagnosed (12). There is no specific biomarker and cultures may be negative. Moreover, thrombocytopenia in hematological diseases may preclude extraction of tissue specimens for diagnosis. Therefore, the disease is usually diagnosed at a much later stage, or even post-mortem in almost 85% patients (13).

Pulmonary infection can present as a non-resolving pneumonia, cavitation, air-crescent sign, halo sign, reverse halo sign, pulmonary mass, nodules, bronchopulmonary fistulae, pleural effusions or lymphadenopathy (14). The radiographic picture is not different from that of aspergillosis, and hence may lead to voriconazole use, which can be detrimental. This infection has a predilection for invasion into adjacent structures and vessels, which becomes the basis for cardiac involvement with pulmonary mucormycosis. Cardiac mucormycosis has not been extensively reported in the medical literature and most cases are diagnosed on autopsy (15). The hallmark of infection is presence of septic fungal thrombosis containing non-branching aseptate hyphae enmeshed with fibrin and leucocytes. These thrombi can invade the myocardium or endocardium causing infarctions by blockage of small myocardial blood vessels. Acute myocardial infarction has also been reported due to blockage of major epicardial arteries. There may be endocarditis, myocarditis and pericarditis (16). Left atrium and ventricle are the most common cardiac chambers affected with mural mycotic thrombi. To the best of our knowledge, there are only three case reports of pulmonary antemortem diagnosis with cardiac mucormycosis. Hence, this case of pulmonary mucormycosis invading to heart and diagnosed antemortem, is unique.

Amphotericin B has been used for medical treatment of mucormycosis, with its liposomal form preferred due to less toxicity. Newer drugs have been introduced namely: posaconazole, isavuconazole and echinocandins. While posaconazole has shown promising outcomes, Amphotericin B remains the first-line drug with posaconazole used as a salvage therapy (17). However, it has been proven that management of mucormycosis is multi-modal with surgical management and treatment of the underlying condition as important in antifungal therapy.

Our patient had a unique presentation with a newly diagnosed ALL, which came to light due to

disseminated fungal pneumonia. Although we kept a high index of suspicion from the outset and gave her Liposomal Amphotericin B, the disease progressed. This emphasizes the superiority of multi-pronged management, comprised of both medical and surgical approaches.

In conclusion, disseminated mucormycosis is a rare entity that warrants early diagnosis and aggressive management. With an increase in the immunocompromised population, the incidence of mucormycosis is expected to rise in the future. A high index of suspicion is necessary as the diagnosis of mucormycosis can be elusive. Medical management, surgical therapy and treatment of the underlying disease all go hand-in-hand for management of these patients.

References

1. Keng MK, Sekeres MA. Febrile neutropenia in hematologic malignancies. *Curr Hematol Malig Rep*. 2013; 8:370-378.
2. Kauffman CA, Malani AN. Zygomycosis: An emerging fungal infection with new options for management. *Curr Infect Dis Rep*. 2007; 9:435-440.
3. Katragkou A, Walsh TJ, Roilides E. Why is mucormycosis more difficult to cure than more common mycoses? *Clin Microbiol Infect*. 2014; 20:74-81.
4. Mititelu R, Bourassa-Blanchette S, Sharma K, Roth V. Angioinvasive mucormycosis and paradoxical stroke: A case report. *JMM Case Rep*. 2016; 3:e005048.
5. Gubarev N, Separovic J, Gasparovic V, Jelic I. Successful treatment of Mucormycosis endocarditis complicated by pulmonary involvement. *Thorac Cardiovasc Surg* 2007; 55:257-258.
6. Muqheetadnan M, Rahman A, Amer S, Nusrat S, Hassan S, Hashmi S. Pulmonary mucormycosis: An emerging infection. *Case Rep Pulmonol*. 2012; 2012:120809.
7. Chakrabarti A, Chatterjee SS, Das A, Panda N, Shivprakash MR, Kaur A, Varma SC, Singhi S, Bhansali A, Sakhuja V. Invasive zygomycosis in India: Experience in a tertiary care hospital. *Postgrad Med J*. 2009; 85:573-581.
8. Petrikkos G, Skiada A, Lortholary O, Roilides E, Walsh TJ, Kontoyiannis DP. Epidemiology and clinical manifestations of mucormycosis. *Clin Infect Dis*. 2012; 54:S23-S34.
9. Gleissner B, Schilling A, Anagnostopoulos I, Siehl I, Thiel E. Improved outcome of zygomycosis in patients with hematological disease? *Leuk Lymphoma*. 2004; 45:1351-1360.
10. Hsu LY, Lee DG, Yeh SP, Bhurani D, Khanh BQ, Low CY, Norasetthada L, Chan T, Kwong YL, Vaid AK, Alejandria I, Mendoza M, Chen CY, Johnson A, Tan TY. Epidemiology of invasive fungal diseases among patients with hematological disorders in the Asia-Pacific: A prospective observational study. *Clin Microbiol Infect*. 2015; 21:594.e7-11.
11. Atkinson JB, Connor DH, Robinowitz M, McAllister HA, Virmani R. Cardiac fungal infections: Review of autopsy findings in 60 patients. *Hum Pathol*. 1984; 15:935-942.
12. Noorifard M, Sekhavati E, Jalaei Khoo H, Hazraty I, Tabrizi R. Epidemiology and clinical manifestations of fungal infection related to mucormycosis in hematological malignancies. *J Med Life*. 2015; 8:32-37.
13. Kontoyiannis DP, Wessel VC, Bodey GP, Rolston KV. Zygomycosis in the 1990s in a tertiary care cancer center. *Clin Infect Dis*. 2000; 30:851-856.
14. McAdams HP, Rosado de Christenson M, Strollo DC, Patz EF Jr. Pulmonary mucormycosis: Radiologic findings in 32 cases. *AJR Am J Roentgenol*. 1997; 168:1541-1548.
15. Virmani R, Connor DH, McAllister HA. Cardiac mucormycosis: A report of five patients and review of 14 previously reported cases. *Am J Clin Pathol*. 1982; 78:42-47.
16. Jackman JD Jr, Simonsen RL. The clinical manifestations of cardiac mucormycosis. *Chest*. 1992; 101:1733-1736.
17. van Burik JA, Hare RS, Solomon HF, Corrado ML, Kontoyiannis DP. Posaconazole is effective as salvage therapy in zygomycosis: A retrospective summary of 91 cases. *Clin Infect Dis*. 2006; 42:e61-e65.

(Received September 18, 2017; Revised October 17, 2017; Accepted October 24, 2017)